

Sagittal Spinal Posture in Relation to Craniofacial Morphology

Carsten Lippold^a; Gholamreza Danesh^a; Gloria Hoppe^b; Burkhard Drerup^c; Lars Hackenberg^d

ABSTRACT

Objective: The aim of this study is to determine correlations between the parameters of body posture in the sagittal profile and sagittal jaw position by obtaining objective and valid three-dimensional measurements of the dorsal profile by means of rasterstereography.

Materials and Methods: Fifty-three adults with Class II or III malocclusions were examined, and six angular parameters were determined. For the sagittal analysis of body posture, the Fleche Cervicale and Lombaire as well as trunk inclination were evaluated.

Results: Statistically significant correlations ($P < .05$) were found between Facial Axis and Fleche Cervicale, Mandibular Plane angle and Fleche Cervicale, and Facial Depth and the Fleche Cervicale.

Conclusions: It can be concluded that the mandible seems to have a greater effect on body posture than other craniofacial parameters. As a clinical result of this study, patients with severe malocclusions should be examined interdisciplinarily before orthognathic surgery is performed to minimize postural influence on the altered jaw relationship after surgery. (*Angle Orthod* 2006;76: 625–631.)

KEY WORDS: Body posture; Craniofacial morphology; Rasterstereography

INTRODUCTION

The orthodontic literature contains indications that there are correlations between orthodontic and orthopedic findings,^{1–8} and this literature was summarized by Korbmacher et al⁴ in a systematic review. In a sequence of studies, the relationship between the posture of the head and cervical inclination was evaluated by a cephalometric assessment of lateral cephalographs.^{1,9–11} Moreover, some studies describe the relationship of the length of the lower jaw and cervical lordosis. Here, Festa et al¹ were able to determine a

statistically significant correlation between distal jaw position, sagittal mandibular length, and increased cervical lordosis. Also, D’Attilio et al⁹ found a statistically significant correlation with mandibular position and length, overjet, and the mandibular plane angle to the cervical curvature.

Michelotti et al⁸ stated that although the relationships between the upper cervical spine and mandibular position are described in the literature, this could not be proven for further caudally located spine sections. In contrast to this, some studies deny the existence of correlations between specific orthopedic findings and certain sagittal jaw positions.^{12,13}

In view of the diagnostic methods used, lateral cephalographs obtained for the purpose of a diagnosis in orthodontics offer a valid means of analyzing parameters such as the sagittal and the vertical jaw position. However, in the orthopedic examination carried out within the framework of the presented studies, objective examination procedures were only rarely used.⁴ Often, forms of bad posture are diagnosed by means of a simple subjective clinical orthopedic examination.^{3,4,6,7}

Yet, apart from the radiographic diagnosis with a specific diagnostic and therapeutic aim, an objective examination of the spine is also possible by means of

^a Research Scientist, Department of Orthodontics, Faculty of Dentistry, University of Münster, Münster, Germany.

^b Research Assistant, Department of Orthodontics, Faculty of Dentistry, University of Münster, Münster, Germany.

^c Professor, Department Technical Orthopedics and Rehabilitation, Faculty of Medicine, University of Münster, Münster, Germany.

^d Professor, Department of Orthopedics, Faculty of Medicine, University of Münster, Münster, Germany.

Corresponding author: Carsten Lippold, University of Münster, Poliklinik für Kieferorthopädie, Waldeyerstr 30, Münster, NRW 48129, Germany (e-mail: lippold@uni-muenster.de)

Accepted: September 2005. Submitted: August 2005.

© 2006 by The EH Angle Education and Research Foundation, Inc.

noninvasive procedures such as rasterstereography, which are highly accurate and can be used in studies without exposing patients to X-rays.^{14–18}

The aim of this study is to determine correlations between the parameters of body posture in the sagittal profile and sagittal jaw position by obtaining objective and valid three-dimensional measurements of the dorsal profile using rasterstereography.

MATERIALS AND METHODS

Fifty-three healthy adults (32 females, 21 males; average age 24.6 years, SD 9.0 years) with skeletal Class II or III malformations who came to our center to consult regarding a combined orthodontic-orthognathic surgery treatment were examined. No comparison group with neutral occlusion (Class I) was established because there was no justification for the exposure of these persons to lateral cephalographs. None of the examined persons revealed anamnesticly determined motor or neurological findings, medicinal diseases, or already existing orthopedic illnesses. All patients were informed of the procedures involved in a clinical examination and they gave written consent to the study procedure. The procedures were carried out according to the criteria of the local Ethics Commission and the Helsinki Declaration.

Cephalometric Analysis

For each of the examined patients, a standardized lateral radiograph (24 × 30-cm film, Planex Regular, Kodak, Germany) was made (Focus—Film distance 3.2 m; enlargement factor 1%; exposure: 15–25 mAs, 72–81 kV). The cephalographs were digitized at 300 dpi (scanner: Power Look III, Umax Systems, Willich, Germany). A cephalometric evaluation (Figure 1) was done using six angular skeletal parameters¹⁹ (Table 1) and orthodontic analyzing software (Onyx Ceph Version 2.7.8, Image Instruments, Chemnitz, Germany).

The sagittal position of the maxilla and the mandible (maxilla position and facial depth), as well as the parameters for the analysis of the vertical craniofacial morphology (inner gonial angle, facial axis, mandibular plane angle, and lower facial height), were considered relevant for this study. The patients' names were blinded to maintain anonymity in the evaluation.

The methodological error within the cephalometric analysis was determined by having the six measurement values analyzed on randomly chosen cephalographs after a 2-week interval by the same examiner. The error was determined by means of the Dahlberg Formula²⁰ (mean error ratio $SE^2 = d^2/2n$, where d = difference between the measurements at two different times; n = number of measurements).

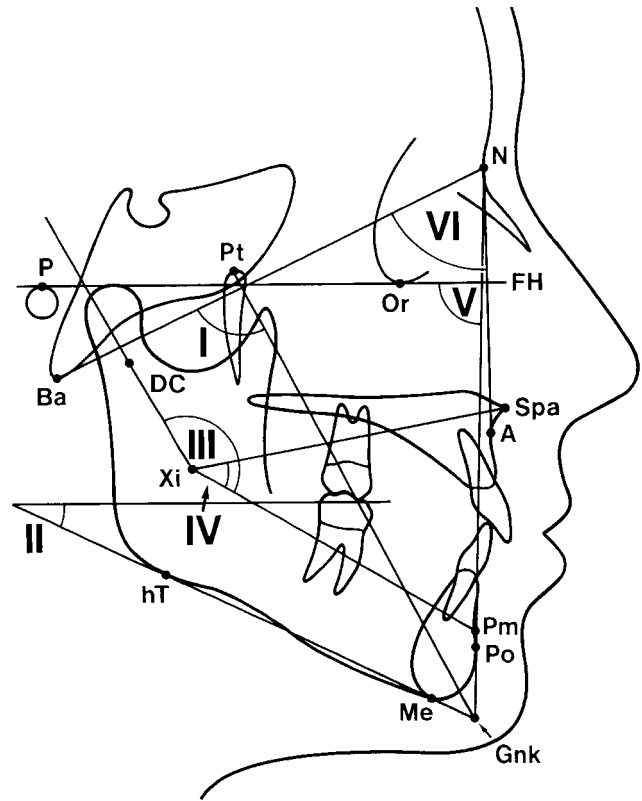


FIGURE 1. Cephalometric analysis: reference points, lines, and angles (I–VI).

Rasterstereography

Rasterstereography^{15,17} (Formetric 2, Diers, Schlangenbad, Germany) is based on photogrammetric methods and reveals a three-dimensional image of the back shape profile (Figure 2a). For this, a light raster emitted by a projection unit is projected on the dorsal surface of a patient standing in a defined manner toward the device. The light raster then determines data about the surface profile via a video-optic unit from another direction.²¹ The measuring speed with 0.04 seconds can be considered quick with the whole dorsal surface being recorded at the same time. Rasterstereography excels by its high precision (methodic error < 0.1 mm) and allows for a radiation-free representation of the profile.

The reproducibility of an individual raster-stereographic picture is indicated for angular measures as 2.8°. By means of the connected software, the anatomic structures (vertebra prominens “VP” and spinae iliacae “SI”; acc. Figure 3b) are anatomically recognized, providing the basis for a reconstruction of the sagittal profile of the back surface.²² Figure 2b shows a typical three-dimensional profile and Figure 2c the automatically produced output protocol in the sagittal direction.

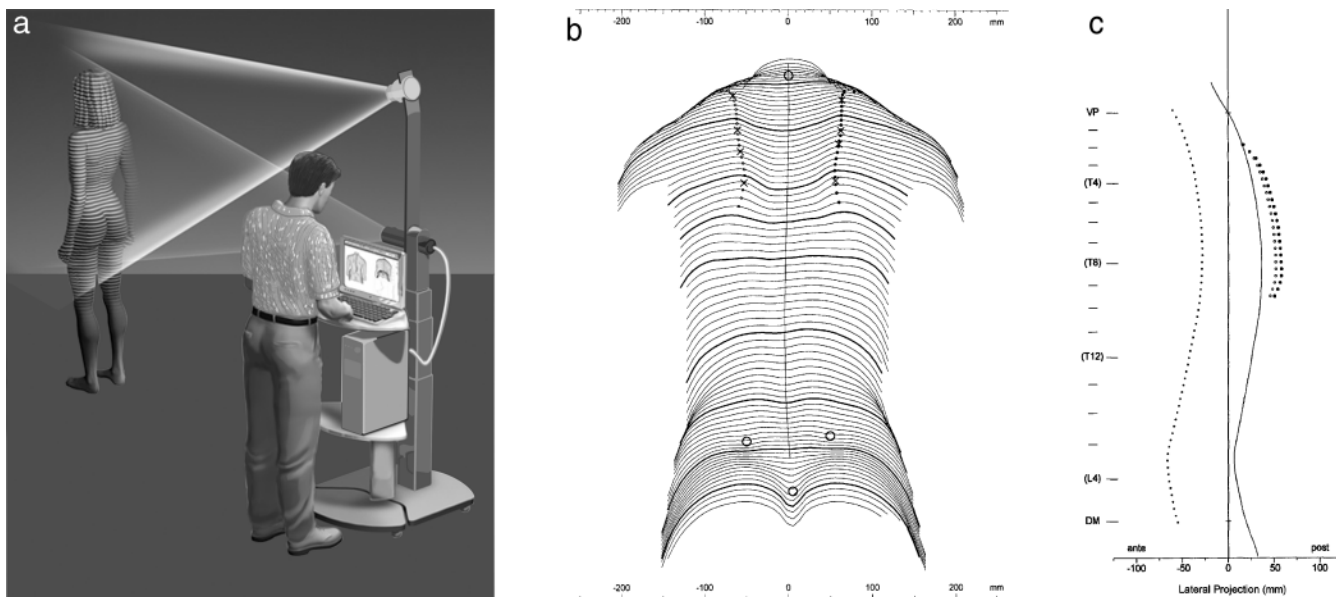


FIGURE 2. (a) Rasterstereography: the measurement process is based on photogrammetry. (b) A rasterstereographic surface reconstruction of the back profile of a patient in this study: transverse profiles and symmetry lines. (c) Lateral projection of the spinal midline based on the three-dimensional surface reconstruction.

By means of mathematical algorithms, a two-dimensional median sagittal dorsal profile is generated. Stagnara²³ and Stagnara et al²⁴ describe the sagittal distance between the lowest point of the cervical spine lordosis and the lumbar lordosis toward the vertical as the “Fleche Cervicale” and “Fleche Lombaire,” respectively (Figure 3a). As another parameter, the trunk inclination in comparison with the vertical of the upright standing patients was determined. This is defined as the angle between the line connecting the vertebral point (VP) and the calculated middle of the right and left spinae iliacae (SI) in relation to the vertical (Figure 3b).

Statistics

SPSS 12.0 (Lead Tech, Chicago, Ill) was used to statistically analyze the measured values. For the purposes of descriptive statistics, the mean values are indicated with standard deviations. The Pearson test was used for the calculation of correlations. The significance level in all tests was determined to be $P < .05$. In the range diagram, R^2 was calculated for further differentiation of the direction of the linear dependence.

RESULTS

The methodic error when evaluating angular measurements on the lateral cephalographs was below 0.5° . This value was applied with reference to Trpkova et al.²⁵

Within the framework of the cephalometric evaluation of the lateral cephalographs, the following values could be determined:

- for the facial axis (I) a mean value of 88.6° (SD 6.0° ; minimum 71.9° , maximum 101.0°);
- for the mandibular plane angle (II) 26.6° (SD 7.8° ; minimum 10.6° , maximum 46.7°);
- for the inner gonial angle (III) 147.1° (SD 7.7° ; minimum 124.5° , maximum 164.0°);
- for the angular lower facial height (IV) 46.9° (SD 6.9° ; minimum 34.0° , maximum 65.1°);
- for the face depth (V) 88.2° (SD 7.0° ; minimum 75.0° , maximum 102.3°);
- for the maxilla position (VI) 61.4° (SD 5.0° ; minimum 52.8° , maximum 75.0°).

The evaluation of the raster-stereographic pictures revealed:

- for the Fleche Cervicale a mean value of 39.4 mm (SD 14.2 mm; minimum 11.0 mm, maximum 67.6);
- for the Fleche Lombaire 39.3 mm (SD 13.1 mm; minimum 12.7 mm, maximum 72.7 mm);
- for the trunk inclination 1.7° (SD 2.4° ; minimum -3° , maximum 6.1°).

The results of the correlation calculation are shown in Table 2. Statistically significant correlations ($P < .05$) were found between the facial axis and the Fleche Cervicale, the mandibular plane angle and the Fleche Cervicale, and the facial depth and the Fleche Cervicale. To determine the direction and the

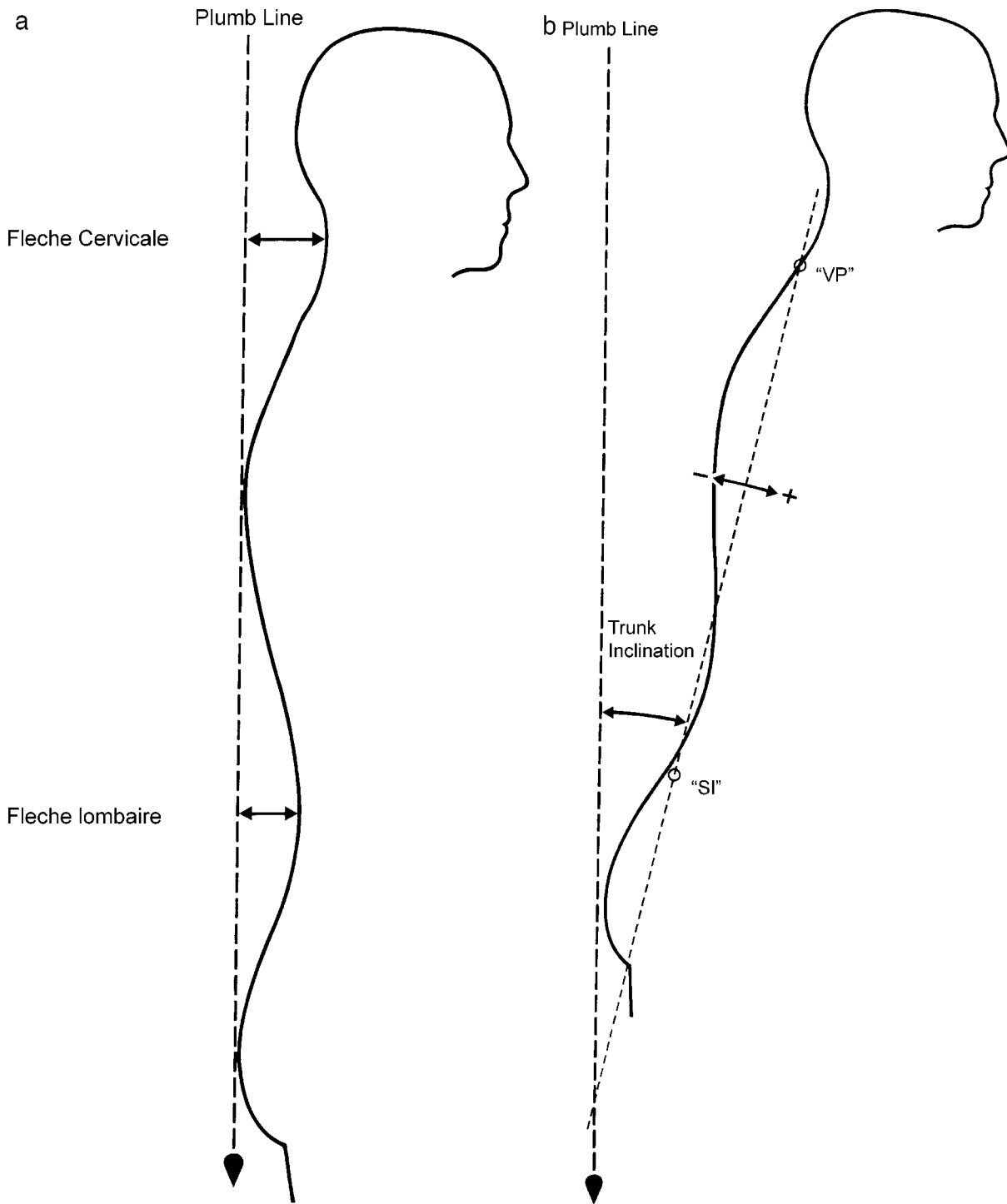


FIGURE 3. (a) Outline of the sagittal profile, the plumb line Fleche Cervical, and Fleche Lombaire. (b) Trunc Inclination measured as the angle between the plumb line and the line between vetebra pomimens (VP) and the middle between the right and left spina iliaca (SI).

strength of the dependency the following values were determined.

For the relationship of the parameter Fleche Cervicale:

- in respect of the facial axis $R^2 = 0.074$;

- in respect of the mandibular plane angle $R^2 = 0.127$;
- in respect of the facial depth $R^2 = 0.075$.

For the trunk inclination and the Fleche Lombaire:

- no statistically significant correlations to the cephalometric values were determined.

Table 1.

I	Ba-N–Pt-Gnk	Facial Axis
II	P-Or–Me-hT	Mandibular Plane Angle
III	Xi-DC–Xi-Pm	Inner Gonial Angle
IV	Xi-Spa–Xi-Pm	Lower Facial Height
V	P-Or–N-Po	Facial Depth
VI	Ba-N–N-A	Maxillary Position

DISCUSSION

In the literature, objective examination methods for a valid study of the correlation between body posture and jaw position are postulated to verify the body posture and the jaw position which should make it possible to obtain valid results.^{4,8} This study is based on exact cephalometric measuring values for which a low methodological error could be proven. Thus, the precondition of objectifying the results has been fulfilled. An examination of the skeletal posture using objective methods could also have been carried out by radiographs of the thorax.²⁶ Considering the radiation exposure of the patient, however, this approach would be not justified for a clinical study.

Therefore, a procedure was chosen for the sagittal analysis of body posture (trunk inclination, Fleche Cervical, and Lombaire) that represents a video-optic method to measure the dorsal surface without using ionizing radiation^{21,27} and excels with very high accuracy. On a clinical level this was confirmed by Drerup et al¹⁶ on scoliosis patients and in comparison with customary cephalographs of the thorax, by Hackenberg et al.^{14,18}

The great dispersion of the cephalometric measuring values obtained from the lateral cephalographs results from the specific range of patients. These were referrals for the implementation of combined orthodontic surgery treatments, which are only indicated in the case of distinct forms of dysgnathia. Thus, only patients with Angle Class II and III were examined as well as vertical forms of malocclusions. No reference was made to the dental parameters because, due to

the natural compensation of the malocclusion, they do not say anything about the degree of the skeletal dysplasia. Because there was no justification for the preparation of lateral radiographs, no patient group with neutral sagittal or vertical skull relation was established.

Analyzing the correlation between Fleche Lombaire and the vertical jaw relation, a significant value could be determined for the facial axis. By evaluating the respective range diagram, the direction of the dependency was determined. Patients with horizontal craniofacial morphology (facial axis >90°) displayed a greater distance between the lowest point of the spine lordosis and the vertical plumb line than those with vertical craniofacial morphology. The sagittal mandibular position (facial depth) revealed a statistically significant correlation to the Fleche Cervicale. In the case of patients with a mesial mandibular position, higher values were measured than in the case of those with a distal position. The position of the mandibular plane in respect of the Frankfort horizontal is characterized by the angle of the mandibular plane, which is correlated to the Fleche Cervical in the case of the examined patient group. Probands with a skeletal “vertical” mandibular type revealed less distance between the vertical and the lowest point of the spinal lordosis.

Because the documented correlations measured for the upper spine area (Fleche Cervicale) and the sagittal and the vertical mandibular position are based on angular parameters relating not to the upper jaw but to the lower jaw, it can be concluded that the lower jaw is more closely related to the musculoskeletal anatomy of the cervical spine. In the literature, this is explained by the tight spatial and neuronal (sensory and motor) entwinement of these structures.^{4,6,7,10}

In accordance with studies describing the inclination of the upper spine sections toward the craniofacial morphology,^{9–12,28,29} we were able to determine a correlation of these areas. Moreover, the method we used enabled us to assess not only the cervical spine by means of the video-stereography but also the struc-

Table 2.

	Statistics									
					Trunk Inclination		Fleche Cervicale		Fleche Lombaire	
	Mean	SD	Minimum	Maximum	P value	r ²	P value	r ²	P value	r ²
Facial Axis	88.7	6.0	71.9	101.0	.113	0.049	.049*	0.074	.271	0.024
Mandibular Plane	26.6	7.8	10.6	46.7	.140	0.042	.009**	0.127	.572	0.006
Inner Gonial Angle	147.1	7.7	124.5	164.0	.900	0.029	.182	0.035	.648	0.004
Lower Facial Height	47.0	7.0	34.0	65.1	.170	0.037	.230	0.028	.333	0.018
Facial Depth	88.2	7.0	75.0	102.3	.526	0.008	.047*	0.075	.899	0.008
Maxilla Position	61.4	5.0	52.8	75.0	.462	0.011	.583	0.006	.476	0.01

* Significant.

** Highly significant.

tures below this area (thoracic and lumbar spine sections). In this study, no correlations between the Fleche Lombaire and the trunk inclination could be found in the case of patients with different sagittal or vertical craniofacial morphology.

These results conform to the statements made by Michelotti et al,⁸ who reported the correlations between jaw position and body posture for the upper spine sections but not for lower spine sections. The noninvasive examination method of the body posture reveals possibilities for the analysis of the prospective development between the jaw position and body posture in the case of children and youths. Studies of these groups should also include the possible influence of orthodontic therapy.

It would be interesting to know how much modification of the sagittal or vertical relationship of the craniofacial morphology by means of an operative mandibular transposition combined with orthodontics and with the subsequent modification of the balance in the musculoskeletal area would also automatically influence the sagittal spine static. Further clinical studies could examine the possible influence of jaw-shifting surgery on the spine position to provide prognostic indications for the interaction of the dentition and the spine in the case of patients before orthognathic surgery.

CONCLUSIONS

- In the case of patients with skeletal malformations of Angle Class II and III as well with a high degree of vertical craniofacial morphology, this study provides evidence for a relationship between the jaw position and the body posture in the upper part of the spine and excludes any connection for the lower part of the spine—at least within the framework of this study.
- Further examinations are necessary to analyze the prospective development of the mandibular position and the body posture in the case of children and youths. Here the possible influence of an orthodontic therapy on the body posture also should be considered.
- As a clinical consequence of our own results, an extension of the multidisciplinary concept in the sense of a noninvasive orthopedic examination could be considered for patients undergoing a combined orthodontic-surgery therapy.

REFERENCES

1. Festa F, Tecco S, Dolci M, Ciuffolo F, Di Meo S, Filippi MR, Ferritto AL, D'Attilio M. Relationship between cervical lordosis and facial morphology in Caucasian women with skeletal

- class II malocclusion: a cross sectional study. *Cranio*. 2003;21:121–129.
2. Gresham H, Smithells PA. Cervical and mandibular posture. *Dent Rec*. 1954;74:261–264.
3. Hirschfelder U, Hirschfelder H. Sagittale Kieferrelation und Wirbelsäulenhaltung: untersuchungen zur Frage einer Abhängigkeit. *Fortschr Kieferorthop*. 1987;48:436–448.
4. Korbmacher H, Eggers-Stroeder G, Koch L, Kahl-Nieke B. Correlations between anomalies of the dentition and pathologies of the locomotor system—a literature review. *J Orofac Orthop*. 2004;65:190–203.
5. D'Attilio M, Epifania E, Ciuffolo F, Salini V, Filippi MR, Dolci M, Festa F, Tecco S. Cervical lordosis angle measured on lateral cephalograms; findings in skeletal class II female subjects with and without TMD: a cross sectional study. *Cranio*. 2004;22:27–44.
6. Lippold C, van den Bos L, Ehmer U. Beziehungen zwischen kieferorthopädischen und orthopädischen Befunden. *Man Med*. 2000;38:346–350.
7. Lippold C, van den Bos L, Hohoff A, Danesh G, Ehmer U. Interdisciplinary study of orthopedic and orthodontic findings in pre-school infants. *J Orofac Orthop*. 2003;64:330–340.
8. Michelotti A, Manzo P, Farella M, Martina R. Occlusion and posture: is there evidence of correlation? *Minerva Stomatol*. 1999;48:525–534.
9. Huggare JAV, Cooke MS. Head posture and cervicovertebral anatomy as mandibular growth predictors. *Eur J Orthod*. 1994;16:175–180.
10. Nobili A, Adversi R. Relationship between posture and occlusion: a clinical and experimental investigation. *Cranio*. 1996;14:274–285.
11. Solow B, Sandham A. Cranio-cervical posture: a factor in the development and function of the dentofacial structures. *Eur J Orthod*. 2002;24:447–456.
12. Solow B, Tallgren A. Dentoalveolar morphology in relation to craniocervical posture. *Angle Orthod*. 1977;47:157–164.
13. Sterzik G, Graßhoff H, Lentschow B. Morphologische Verknüpfungen von Euginathien, Gebißanomalien der Klasse II/1 und Klasse III mit Veränderungen der Topographie der Halswirbelsäule im Fernröntgenseitenbild. *Fortschr Kieferorthop*. 1992;53:69–76.
14. Hackenberg L, Hierholzer E, Pötzl W, Götze C, Liljenqvist U. Rasterstereographic back shape analysis in idiopathic soliosis after anterior correction and fusion. *Clin Iomech*. 2003;18:1–8.
15. Drerup B, Hierholzer E. Back shape measurement using video rasterstereography and three-dimensional reconstruction of spinal shape. *Clin Biomech*. 1994;9:28–36.
16. Drerup B, Hierholzer E, Ellger B. Shape Analysis of the lateral and frontal projection of spine curves assessed from rasterstereographs. In: Sevastik JA, Diab KM, eds. *Research into Spinal Deformities*. 1st ed. Amsterdam: IOS Press; 1997:271–275.
17. Frobin W, Hierholzer E. Rasterstereography: a photogrammetric method for measurement of body surfaces. *Photogr Eng Remote Sensing*. 1981;47:1717–1724.
18. Hackenberg L, Hierholzer E, Potzl W, Gotze C, Liljenqvist U. Rasterstereographic back shape analysis in idiopathic scoliosis after posterior correction and fusion. *Clin Biomech*. 2003;18:883–889.
19. Proffit WR. *Contemporary Orthodontics*. 3rd ed. St Louis, Mo: Mosby; 2000.
20. Dahlberg, G. *Statistical Methods for Medical and Biological Students*. New York, NY: Interscience Publications. 1940: 122–132.

21. Hierholzer E, Drerup B. High-resolution rasterstereography. In: D'Amico M. et al, eds. *Threedimensional Analysis of Spinal Deformities*. Amsterdam, Oxford, Washington: IOS Press; 1995:435–439.
22. Drerup B, Hierholzer E. Automatic localization of anatomical landmarks on the back surface and construction of a body-fixed coordinate system. *J Biomech*. 1987;20:961–970.
23. Stagnara P. Ambulante orthopädische Behandlung der Scheuermanschen Krankheit im floriden Stadium. *Schweiz med Wschr*. 1965;95:674.
24. Stagnara P, du Peloux J, Fauchet R. Traitement orthopédique ambulatoire de la maladie de Scheuermann en période de dévotion. *Rev chir orthop*. 1966;52:585–600.
25. Trpkova B, Major P, Prasad N, Nebbe B. Cephalometric landmarks identification and reproducibility: a meta analysis. *Am J Orthod Dentofacial Orthop*. 1997;112:165–170.
26. Vialle R, Levassor N, Rillardon L, Templier A, Skalli W, Guigui P. Radiographic analysis of the sagittal alignment and balance of the spine in asymptomatic subjects. *J Bone Joint Surg Am*. 2005;87:260–267.
27. Drerup B. The measurement of the kyphotic angle by contact free registration of back-shape. *Z Orthop Ihre Grenzgeb*. 1982;120:64–70.
28. Huggare JAV. The first cervical vertebra as an indicator of mandibular growth. *Eur J Orthod*. 1989;11:10–16.
29. Solow B, Siersback-Nielsen S. Cervical and craniocervical posture as predictors of craniofacial growth. *Am J Orthod Dentofacial Orthop*. 1992;101:449–458.