

Manual Therapy of the Mandibular Accessory Ligaments for the Management of Temporomandibular Joint Disorders

Antonino Marco Cuccia, DDS
Carola Caradonna, DDS
Domenico Caradonna, MD, DDS

Temporomandibular joint disorders are characterized by chronic or acute musculoskeletal or myofascial pain with dysfunction of the masticatory system. Treatment modalities include occlusal splints, patient education, activity modification, muscle and joint exercises, myofascial therapy, acupuncture, and manipulative therapy. In the physiology of the temporomandibular joint, accessory ligaments limit the movement of the mandible. A thorough knowledge of the anatomy of accessory ligaments is necessary for good clinical management of temporomandibular joint disorders. Although general principles regarding the anatomy of the ligaments are relatively clear, very little substantiated information on the dimension, orientation, and function of the ligaments has been published, to the authors' knowledge. The authors review the literature concerning the accessory ligaments of the temporomandibular joint and describe treatment options, including manual techniques for mobilizing the accessory ligaments.

J Am Osteopath Assoc. 2011;111(2):102-112

The stomatognathic system is characterized by several structures including skeletal components (eg, maxilla, mandible), dental arches, soft tissues (eg, salivary glands, nervous and vascular supplies), masticatory muscles, and the temporomandibular joint (TMJ). These structures act in harmony to perform different functional tasks such as speaking, chewing, and swallowing.¹ This system includes also the hyoid bone and the muscles that connect it to the manubrium of sternum, mandible, scapula, the facial sheets within the anterior cervical region, and other structures in the neck.

The TMJ makes muscular and ligamentous connections to the cervical region, forming a functional complex called the cranio-cervico-mandibular system. The TMJ is a synovial joint consisting of the condyle of the mandible, the mandibular fossa of the temporal bone, a thin articular disk, and a capsule (*Figure 1*). The TMJ is responsible for all movements of the jaw, which take place in different orthogonal planes and around multiple axes of rotation. These movements allow a number of functions such as chewing, sucking and swallowing, articulating sounds, breathing, and making facial expressions. The TMJ works properly when the right-sided and left-sided joints are synchronized during movement.

Pain associated with temporomandibular joint disorders (TMDs) is thought to originate in the synovial joint capsule and surrounding musculature. Branches of the auriculotemporal, masseteric, and posterior deep temporal nerves supply the TMJ; it is still uncertain whether branches of the facial nerve and the lateral pterygoid nerve supply the joint.² Branches from internal maxillary, superficial temporal, transverse facial, and middle meningeal arteries also supply the TMJ.³

In the TMJ, proprioception is provided principally by the capsule, spindles of masticatory muscles, cutaneous receptors, and periodontal mechanoreceptors.⁴ The articular surface of the joint, covered by a fibrous connective tissue, is avascular and noninnervated. This structure has a greater capacity to resist degenerative change and regenerate itself than the hyaline cartilage of other synovial joints.⁵

Articular disks, masticatory muscles, capsules, and ligaments stabilize the condyle in TMJs. The TMJ is stable particularly because fibrous ligaments protect the joint from stress and tension; they are arranged so that during movements of the jaw, they pull the articular surface together.

TMJ Disorders

Temporomandibular joint disorder is a collective term that describes a number of clinical problems that involve the hard and soft tissue structures of the TMJ (eg, joint surfaces, capsule, articular disk, ligaments, masticatory muscles). Symptoms may include clicking or grating within the joint, mechanical restrictions (eg, limited jaw opening capacity, deviations in the movement patterns of the mandible), headache, neck pain, or stiffness.^{6,7}

Diagnosis of TMD should include careful palpation of the TMJ (observing the midincisural line for deviation from the

From the Department of Dental Sciences ("G. Messina") at the University of Palermo in Italy.

Financial Disclosure: None reported.

Address correspondence to Antonino Marco Cuccia, DDS, Department of Dental Sciences ("G. Messina"), University of Palermo, Via del Vespro 129, 90128 Palermo, Italy.

E-mail: cucciaam@odonto.unipa.it

Submitted October 26, 2009; final revision received May 17, 2010; accepted September 15, 2010.

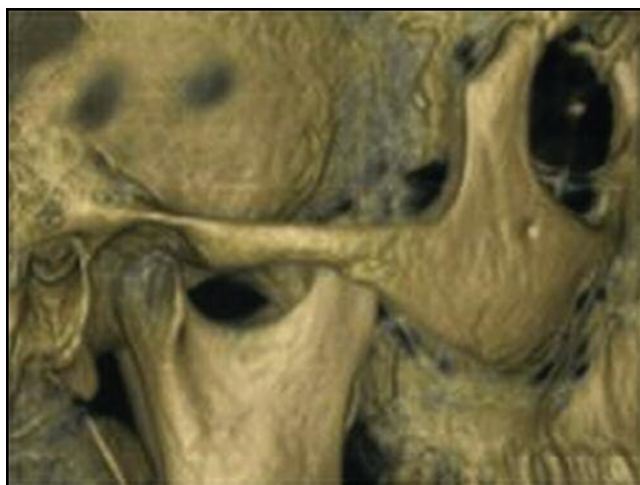

Figure 1. Computerized 3-dimensional reconstruction with direct volume rendering from a sagittal magnetic resonance image of the right-sided temporomandibular joint region of a 28-year-old man.

midline), masticatory muscles, and neck, as well as diagnostic tests including the temporomandibular index test, which measures the severity of the disorder,⁸ and the visual analog scale, which records the intensity of pain.⁹

The prevalence of signs and symptoms of TMD in the general population varies according to the different studies examined. The guidelines of the American Academy of Orofacial Pain estimates 40% to 75% of the population displays at least 1 sign of the disease and 33% of the population reports at least 1 symptom.¹⁰ However, only 5% of adults with TMD symptoms require treatment and even fewer develop chronic or debilitating symptoms. The disorder is 1.5 to 2 times more prevalent in women than in men. Pain tends to occur after puberty, with the highest prevalence occurring in women aged 20 to 40 years. The sex and age distribution of TMD suggests a possible link between its pathogenesis and the female hormonal axis.¹¹

The origin of TMD is likely multifactorial. Microtrauma, macrotrauma, abnormal occlusion, abnormalities of the articular disk and the articular surfaces, parafunctional habits (eg, bruxism), anxiety, stress, and other conditions may cause inflammation or damage to the TMJ's capsule and ligaments or cause muscle pain or spasm.¹²⁻¹⁴ In particular, excessive or protracted mechanical loads activate molecular cascades (eg, the release of free radicals, proinflammatory neuropeptides, or potent cytokines) that culminate in degenerative joint disease.¹⁵ Upledger¹⁶ stated that TMD may originate from sacral dysfunction.

Temporomandibular joint disorders are some of the more difficult conditions to manage, and management is frequently multifactorial and multidisciplinary. Several available therapies

are listed in *Figure 2*.¹⁷ These interventions are commonly used to reduce pain and to improve mandibular range of motion. Absence of pain, improved TMJ function, and normal quality of life are appropriate markers of treatment success. Moreover, a recent study has suggested that a diet rich in omega-3 fatty acids, vitamin E, and vitamin C may offer protection from TMD because of these nutrients' anti-inflammatory and antioxidant properties.¹⁸

Although various authors have described several techniques for treating patients with TMD, few published studies have focused on the management of the accessory ligaments of the TMJ, to our knowledge.¹⁷⁻¹⁹ We consider the clinical anatomy of these ligaments and their role in the etiology of TMD as well as suggest manual techniques specific to these ligaments for the treatment of patients with TMD.

Accessory Ligaments of the TMJ

Skeletal ligaments, which stabilize joints and help guide them through their normal range of motion, are dense bands of connective tissue containing fibroblasts, collagen, and elastic fibers. These bands are closely interlaced with one another

- **Dental**
 - dental occlusal splinting (oral appliances)
 - dental regulation
 - permanent occlusal adjustment (dental prosthesis, orthodontics)
- **Pharmacologic**
 - acetaminophen
 - anxiolytics
 - benzodiazepines
 - muscle relaxants
 - nonsteroidal anti-inflammatory drugs
 - tricyclic antidepressants
 - intra-articular corticosteroids or anesthetic injections
- **Manual**
 - osteopathic manual therapy and osteopathic manipulative treatment
 - massage
 - chiropractic
- **Mind-Body Based**
 - meditation
 - relaxation techniques
 - stress management
 - cognitive behavior therapy
- **Other**
 - acupuncture
 - biofeedback
 - iontophoresis
 - phonophoresis
 - transcutaneous electrical nerve stimulation
 - surgery

Figure 2. Therapies for temporomandibular joint disorders.¹⁷

REVIEW

and present a white, shiny aspect. They appear to tighten or loosen depending on bone positions and the forces that are applied. Although ligaments are pliant and flexible to allow freedom of movement, they are nevertheless strong, tough, and unable to extend. Their inherent collagen elasticity is neutralized by the crisscrossed layers of their fibers. However, white elastin between each layer of the ligament allows some movement between the layers. Ligaments also have a role in joint proprioception by helping to provide referred conscious perception of skeletal position.²⁰

Ligaments are more efficient than muscles because they use no energy and are more reliable because they cannot be stretched without damage. Osborn²¹ affirms that mechanical controls have replaced some neuromuscular controls as a result of the evolution of accessory ligaments around joints.

The TMJ includes the following ligaments: lateral (or temporomandibular), lateral collateral, medial collateral, Tanaka, anterior ligament of the malleus, Pinto, sphenomandibular, stylo-mandibular, and pterygomandibular. Like the accessory ligaments around all joints, those around the TMJ help to stabilize it by keeping the joint surface in optimal anatomic contact.²²

Damage to any of these components can alter the mechanics of the TMJ, affecting the opening and closing motions of the mouth. The sphenomandibular, stylo-mandibular, and pterygomandibular ligaments, considered accessory ligaments, support and protect the joint during wide excursion. Stretching of these ligaments is associated with disunity of the articular disk and the condyle, hypermobility, and temporomandibular dislocation (Figure 3).²¹

Sphenomandibular Ligament

The sphenomandibular ligament (SML) is a remnant of Meckel cartilage. The ligament originates solely from the spine of the sphenoid bone in only about one-third of individuals.²³ In the majority of individuals, it also inserts into the medial wall of the joint capsule, through the petrotympanic fissure, and in the anterior process of the malleus, where its fibers form a portion of the anterior ligament of the malleus, which is 30 mm to 34 mm long.²⁴ The ligament then runs downward and outward to insert on the lingula of the mandibular ramus with a 50° angle of inclination (Figure 4). The ligament is pierced by the mylohyoid nerve and vessels.²⁵ From the base of the spine of the sphenoid bone arises also the pterygospinous ligament, the articular capsule, the anterior ligament of the malleus, and the pterygomandibular fascia.^{26, 27}

For the present report, we measured the angulation of the SML and other ligaments in 15 skulls, complete with mandibles and in normal states, at the Department of Biomorphology and Biotechnologies at the University of Messina in Italy, and at the Department of Legal Medicine and the Department of Dental Sciences ("G. Messina") at the University of Palermo in Italy. The results of the measurements are reported in the Table.

The attaching style of the SML to the mandibular ramus

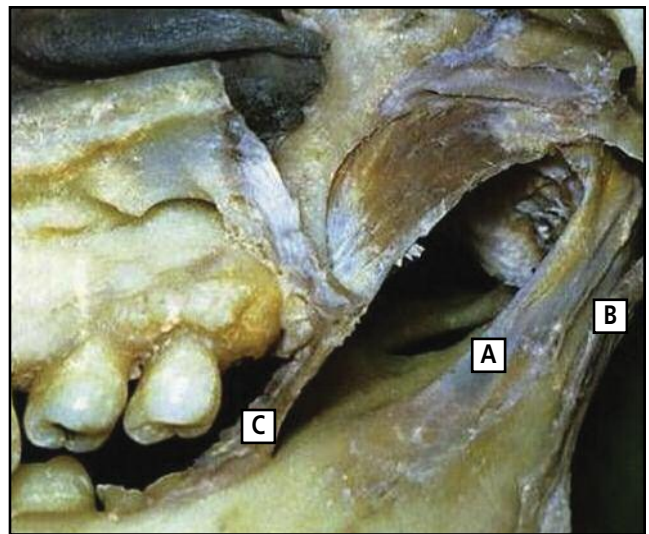


Figure 3. Image of the (A) sphenomandibular, (B) stylo-mandibular, and (C) pterygomandibular accessory ligaments to the temporomandibular joint.

is classified into 3 types. In type I, the SML attaches only to the mandibular lingula; in type II, the SML attaches to the mandibular lingula and extends toward the rear part of the internal surface of the mandibular ramus; and in type III, the SML attaches to the mandibular lingula and extends toward the posterior border of the mandibular ramus. In the type III attaching style, the ligament covers a larger area over the mandibular foramen than in type I. Consequently, the ligaments range in shape from thin bands that descend for a short distance from the spine of the sphenoid bone to broad, biconcave ligaments with prominent insertions. When the mandible

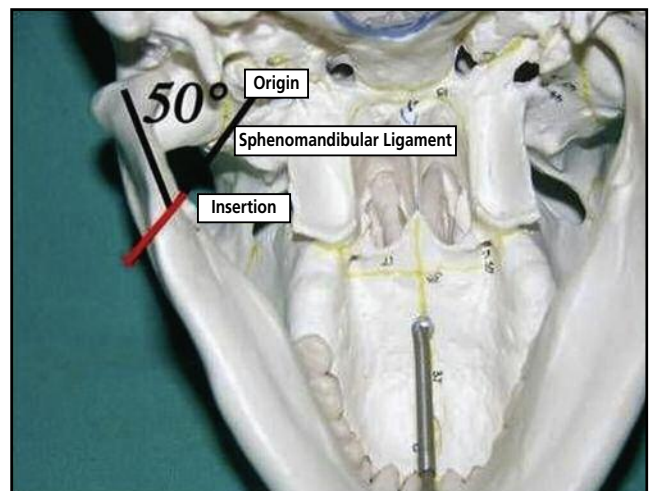


Figure 4. Angle of inclination between the principal axis of the sphenomandibular ligament and the inner surface of the ramus of the mandible.

Ligament	Mean	Range
Sphenomandibular	50.05	43-57
Stylomandibular	35.40	23-37
Pterygomandibular	70.00	62-78

is in the rest position, the SML is relaxed. As long as the condyle is rotating against the articular protuberance without leaving the articular fossa, the ligament becomes progressively more relaxed. When the mouth first opens, it is controlled by the backwardly inclined temporomandibular ligament. Once the mouth opens more than 10° (the beginning of translation), the temporomandibular ligament loses control of the condyle, and the SML becomes taut, particularly when the condyle passes ahead of the articular summit. It is through this process that the temporomandibular ligament replaces the SML to squeeze the condyle against the glenoid slope.²¹

For this motion, the SML, although typically considered an accessory ligament, serves a function of primary importance. It constitutes the primary passive support of the mandible, with the lingual area acting as an anchor.

Stylomandibular Ligament

The styloid process is a slender, pointed piece of bone that extends down and forward from the inferior surface of the temporal bone, immediately in front of the stylomastoid foramen, just below the ear, and within the maxillo-vertebro-pharyngeal space. Important anatomic structures are located in the maxillo-vertebro-pharyngeal space, such as both carotid arteries; the internal jugular vein; and the facial, glossopharyngeal, vagus, and hypoglossal nerves.

The normal length of the styloid process is 20 mm to 25 mm in adults, with an average angulation of 70° .²⁸ The styloid process and ligament are derived from the first and second branchial arches as well as Reichert cartilage.²⁹

Muscles and ligaments are attached at various locations of the process. The attached muscles are the stylopharyngeus (arising from the base), the stylohyoid (attached to the middle portion), and the styloglossus (originating from the extremity of the process). Together, these muscles form the so-called Riolo's bouchet.²⁴ The innervations of these 3 muscles are the glossopharyngeal nerve, the facial nerve, and the hypoglossal nerve, respectively.³⁰ The attached ligaments are the stylohyoid and stylomandibular ligaments, as well as the parotid fascia (a layer of deep cervical fascia of the neck), which contains the parotid gland.³¹

When the styloid process is longer than 25 mm or the stylohyoid ligament is calcified, pharyngeal and cervical pain can occur during swallowing, speaking, or opening the mouth, as well as during movement of the cervical region, sensation

of a foreign body in the oropharynx, or pain radiating to the ear.³²

The stylomandibular ligament (STML) is a specialized dense, local concentration of deep cervical fascia extending from the apex of the styloid process. It is inserted medially into the angle and posterior border of the mandible with a 30° angle of inclination (Figure 5).

The ligament is, on average, 40 mm to 45 mm long and extends forward as a broad fascial layer covering the inner surface of the medial pterygoid muscle, separating the parotid from the submandibular glands. The STML relaxes when the mandible closes and opens widely. This ligament becomes taut only during extreme protrusive movements (eg, restricting the advancement of the mandible) and maximum, forceful hinging of the jaw, helping regulate the movements of the mandible.³¹

The STML could also have an important role in structural support in the angle of the mandible. This ligament, described as a thickening of deep cervical fascia, is a consistently occurring connective tissue band or sheet that extends between the angle of the mandible and the stylohyoid ligament.³³

The STML has an important function, becoming taut when the SML loses control of the condyle—at least when the condyle gets in front of the articular summit. It remains the only stabilizer in extreme, protrusive movements such as maximum, forceful hinging of the jaw.

Pterygomandibular Raphe

The pterygomandibular ligament, also called the *pterygomandibular raphe* (PTR), is a thickening of the buccopharyngeal fascia. The raphe is a narrow band that extends from the apex of the hamulus of the medial pterygoid plate of the skull to the posterior limit of the retromolar trigone of the mandible, with a 70° average angle of inclination on the mandibular

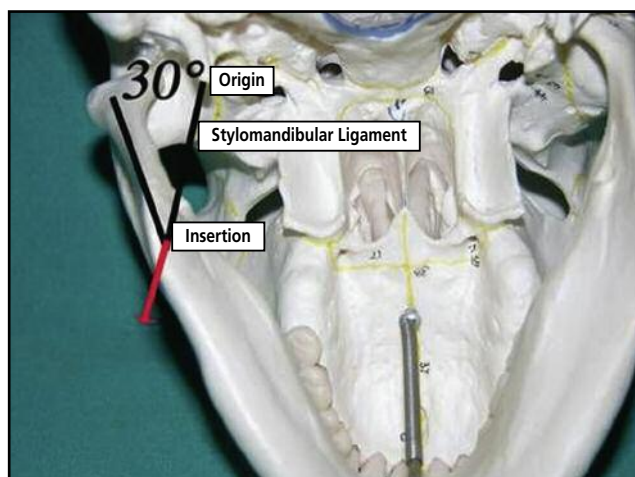


Figure 5. Angle of inclination between the principal axis of the stylomandibular ligament and the inner surface of the ramus of the mandible.

corpus plane (Figure 6). A portion of the buccinator muscle takes origin from its anterior aspect; part of the superior pharyngeal constrictor takes origin from its posterior aspect.

From an embryologic view, the PTR represents a junction region of mesenchymal derivatives from 2 different pharyngeal (branchial) arches. The buccinator muscle receives its innervation from the facial nerve and is considered to be a derivative of the second arch, whereas the superior pharyngeal constrictor receives its innervation from the vagus (cranial accessory) and is considered to be a derivative of the fourth arch.³⁴

The PTR guides the mandible, limiting extreme movements. The ligament is, on average, 25 mm to 30 mm long and produces a vertical fold (ie, the pterygomandibular fold), in the mucous membrane when the mouth is opened.

In a study of adult cadavers, Shimada and Gasser³⁴ identified 3 types of variations in the morphology of the PTR region. In the first type, identified in 28% of cadavers, only the upper portion of the raphe was identified, and it had a broad, triangular shape. In the second type, found in 36% of cadavers, the buccinator and superior pharyngeal constrictor muscles were widely separated by a broad, fascial region. The raphe was absent in the third type of variation, identified in 36% of cadavers, but with complete continuity of the buccinator and superior pharyngeal constrictor muscles.

Dysfunction of the TMJ Accessory Ligaments

The proprioceptive impulses produced by accessory ligaments are mainly transmitted to the mesencephalic nucleus of trigeminal nerve.³⁵ This connection means that any disturbance of the accessory ligaments may also affect the proprioceptive system of the entire stomatognathic system. Therefore, the ligaments have a high sensitivity and inflammatory capacity. If a pain-producing dysfunction in one of these ligaments is suspected, passive movements must be used to test the ligaments. The

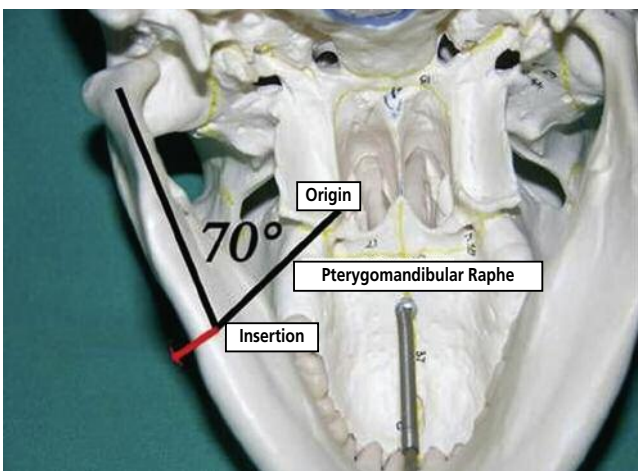


Figure 6. Angle of inclination between the principal axis of the pterygomandibular raphe and the inner surface of the corpus of the mandible.

dysfunction of the accessory ligaments of the TMJ is principally due to direct or indirect trauma to the mandible, to microinjuries, to hypoxia, and to stress.

The stylohyoid and stylomandibular ligaments are known as structures that, when injured, produce throat pain that may spread to the face, ears, and temporomandibular joints. Other symptoms of injury are neuralgic pain, dysphonia, earache, dysphagia, carotidynia, and pain of the styloid process.³⁶

Dysfunction can be due to complications with dental extractions. In particular, the SML, which is attached to the spine of the sphenoid, posterior to the transverse flexion-extension axis of the sphenoccipital synchondrosis, causes a cranial motion (torsion) of the alisphenoid, ipsilateral to the extraction of a molar from the upper jaw and contralateral to the extraction of a molar from the lower jaw, and consequent stretching of the petrosphenoid ligament (Gruber ligament), which delimits the Dorello canal. The Dorello canal is an osteofibrous canal in the dural space beneath the petrosphenoid ligament; between the apex of petrous part of temporal bone and the clivus, which contains the abducens nerve; and inside the confluence of the cavernous, the basilar, and the inferior petrosal sinuses. In dental extraction complications, symptoms can include visual disturbance, facial pain, or tinnitus.

An increase in tension or fibrosis of the ligament causes caudal traction on the base of the sphenoid with a movement of the ipsilateral alisphenoid superior.¹⁸ Because the SML and the STML link the mandible to the base of the skull, a dysfunction of the cranial base may affect the mandible (eg, dysfunction, malocclusion) and vice versa.

Cranial dysfunction may affect TMJ motion; if the temporal bone externally rotates, the mandibular fossa moves posteriorly and medially. Internal rotation allows the mandibular fossa to move anteriorly and laterally. The mandible may deviate toward the side of the externally rotated temporal bone or away from the side of the internally rotated temporal bone.³⁷

Sphenoid and temporal dysfunctions may also affect the TMJ through their direct articulation with the mandible through the SML, STML, and PTR.

Management of the TMJ Accessory Ligaments

Normalization of the primary respiratory movement is important to reduce sacral, spinal, and cranial dura meningeal tension; somatic dysfunctions; torque; and stress through the cranial, sternal, and sacral balancing techniques (Figure 7).^{38,39}

Correct management of the hyoid bone is an additional important objective (Figure 8). By means of the stomatognathic system, the hyoid links the scapula manubrium mandible and cranial base. Any torsion within this area will have consequences for TMJ mechanics. It will also distort the proprioceptive feedback that is essential for control of the whole body posture. Hence, the stomatognathic system should be viewed as a part of the balance control system for the whole body.⁴⁰ Manual medicine and therapy techniques

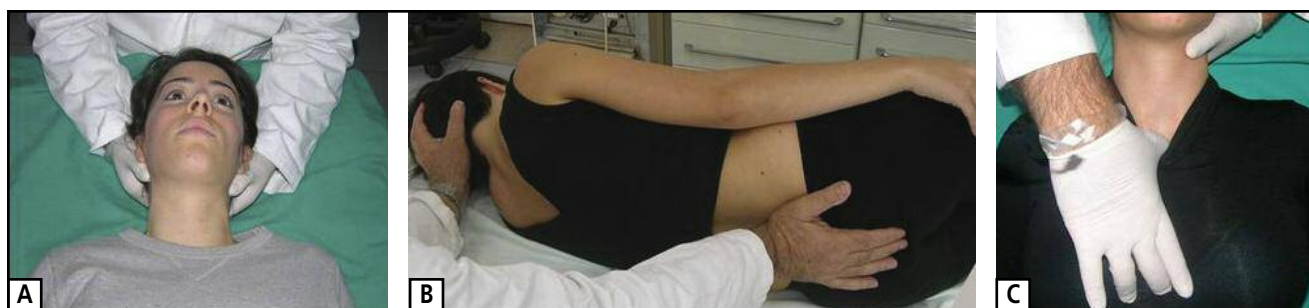

Figure 7. (A) Application of cranial technique, used to assess and manage dysfunction of the temporal bone. Place the palms on the occiput, resting the thenar eminences of each hand bilaterally on the mastoid parts of the temporal bones and the thumbs on the anterior tips of the mastoid process of each side. In the presence of asymmetrical movement of temporal bones, administer an impulse on the tips of the left mastoid process first, and then administer an impulse on the tips of the right mastoid process, following the cranosacral rhythm. Repeat for several cycles. (B) Application of sacral balancing technique. Place

one hand on the occiput and the other hand on the sacrum. Administer gentle clockwise and counterclockwise rotary movements on both points. (C) Application of sternal technique. Grasp the sternum with the thumb on the xiphoid process and the index or middle finger on the jugular incisure of sternum. Place the left hand across the occiput. During the exhalation, administer gentle traction in an inferior direction while the patient performs a plantar extension of the feet. During the inspiration, administer traction in a superior direction while the patient performs a plantar flexion of the feet.

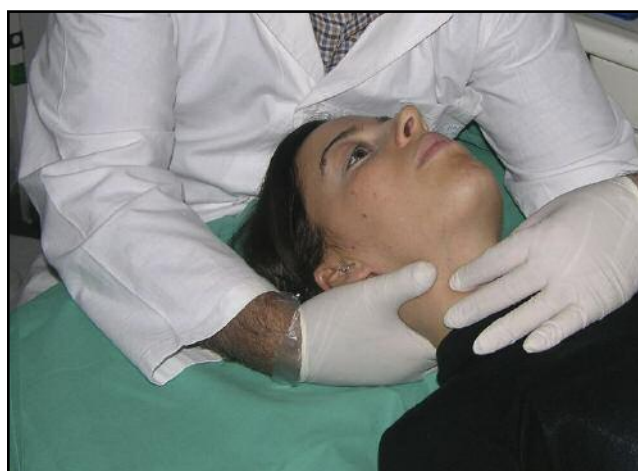

Figure 8. Treatment of the hyoid bone. Use one hand to provide dorsal support for the cervical spine while the other hand spans the hyoid bone between index finger and thumb. Gently test the lateral motion of the hyoid bone and take it to its limit in the direction of ease, in opposite direction to the restriction. Once the tissues soften, seek the new limit of motion. Repeat this process until no further tissue softening can be detected. Then, return the hyoid bone to the neutral position.

PTR of the TMJ and to retrain the involuntary neuromuscular, reflexive control of posture, and balance are described in the Appendix.

Comment

The American Academy of Craniomandibular Disorders and the Minnesota Dental Association have cited physical therapy (eg, electrophysical modalities, therapeutic exercises, manual therapy techniques) as an important treatment modality for the relief of musculoskeletal pain, reduction of inflammation, and restoration of oral motor function.⁴¹

From a broader perspective, the field of manual medicine and manual therapy, which includes OMT, has much to offer in the treatment of patients with TMD. Osteopathic manipulative treatment is characterized by precise manipulative techniques that are less invasive than other interventions and are individually adapted to tissue quality in order to maintain or restore the circulation of body fluids.⁴² However, only a few studies have evaluated the effect of OMT on TMD.⁴³⁻⁴⁵

Ligaments may be regarded anatomically as local thickenings of fascial sheets, which are adapting to increased local tension with a denser and more parallel fiber arrangement. Ligaments contain mechanoreceptors, which provide sensory feedback for muscular coordination. Without their feedback, motor coordination is substantially impaired.⁴⁶

If an excessive joint movement is allowed during the repair process or in the presence of benign joint hypermobility syndrome, a ligament may get longer, leading to a lax joint. A decreased fascial tonus or ligament stiffness can contribute to TMJ instability, which is frequently associated with the onset of pain and resulting hypermobility. Too-long SML and STML may result in instability of the disk and may be the

such as osteopathic manipulative treatment (OMT) in this area can be of great help in returning balance to the body posture. A complete treatment protocol is summarized in Figure 9.

Manipulative treatment techniques for the accessory ligaments of the TMJ form part of the manual medicine protocol for TMD. Specific manipulative procedures designed to reduce the dysfunctions (eg, pain, restriction) of the SML, STML, and

1. muscles, fascia, bones, and viscera with dysfunctions that impair the temporomandibular joint function and postural patterns
2. occipital, temporal, and zygomatic bones to the level of their sutures
3. masticatory muscles
4. hyoid bone muscles
5. sternocleidomastoid muscle and the sternum
6. cranio-cervical fascia
7. condyle and the articular disk
8. sphenomandibular, stylomandibular, and pterygomandibular ligaments

Figure 9. Treatment protocol for patients with temporomandibular joint disorders. Areas should be treated in the order listed.

cause of closed lock. In addition, a temporary decrease of ligament stiffness in cats has been shown to result in the stimulation of fewer ligamentous mechanoreceptors and in decreased periarticular muscle activation.⁴⁷

By contrast, increased tonus of cervical fascia could cause masticatory myofascial pain.⁴⁸ In addition, reduced jaw activity because of pain after trauma, TMD, or splint therapy reduces the amount of stretching to which the ligaments are normally subjected. This reduction in stretching leads to adaptive shortening of the TMJ ligaments because of the laying down of incorrectly oriented and excessively cross-linked collagen.¹³ A too-short SML squeezes the condyle more firmly against the glenoid slope and displaces the disk forward or the condyle back, leading to a lax posterior elastic lamina. A too-short STML, instead, restricts the advancement and the opening of the mandible.

One of the fundamental tasks of manual therapies is to reduce ligament tension to normalize the resting tonus of muscle-fascia-ligament apparatuses, temporarily increasing fascial tone and, consequently, improving fascial proprioception and increasing muscular activation. However, as previously mentioned, the effect of manual therapy techniques on TMD is not clear.

Fibroblasts, which contain α -smooth muscle actin stress fibers and have an innate capacity to display contractile behavior, have been studied. Such cells have been found in various fascias (eg, crural, lumbar). Therefore, it can be cautiously assumed that contractile cells are also present in other dense human fascial sheets, as have already been found in ligaments. Yahia et al⁴⁹ reported an unexpected discovery of fascial behavior, which they termed ligament contraction. Schleip et al⁵⁰ hypothesized that this active fascial contractility can be influenced by manual therapies. In the case of ligament treatment, the correct stimulation of ligaments is important, following the course of the ligament according to the biome-

chanical line of balance, on the grounds of anatomy.

Yin et al⁴⁰ state that the masticatory system is considered to be integrated with proprioceptive, visual, balance, and postural control of the whole body. Each therapy (eg, occlusal splints, masticatory muscle work, lifestyle intervention of oral habits, myofascial therapy, acupuncture, osteopathic medicine) may be more effective than other therapies having significant neurologic implication by means of sensorimotor integration with the brainstem, subcortical and cortical centers, cervical region, proprioception, and body posture. If therapeutic approaches induce appropriate neural plasticity, then it is possible that considerable neurologic improvement of the patient may be achieved. These therapies should be integrated with neurologic monitoring (ie, body balance and coordination control systems).

Conclusion

Following osteopathic principles, it is important to consider the functional interrelation among the head, the neck, the TMJ, and the body as a whole in the management of TMD.

References

1. The Academy of Prosthodontics. The glossary of prosthodontic terms. *J Prosthet Dent.* 1999;81(1):39-110.
2. Langendoen J, Müller J, Jull GA. Retrodiscal tissue of the temporomandibular joint: clinical anatomy and its role in diagnosis and treatment of arthropathies. *Man Ther.* 1997;2(4):191-198.
3. Godlewski G, Bossy J, Giraudon M, Dussaud J, Pavart JC, Lopez JF. Arterial vascularization of the temporomandibular joint. *Bull Assoc Anat (Nancy).* 1978;62(177):229-236.
4. Garg A, Townsend G. Anatomical variation of the sphenomandibular ligament. *Aust Endod J.* 2001;27(1):22-24.
5. Nell A, Niebauer G, Sperr W, Firbas W. Special variations of the lateral ligament of the human TMJ. *Clin Anat.* 1994;7(5):267-270.
6. Hentschel K, Capobianco DJ, Dodick DW. Facial pain. *Neurologist.* 2005;11(4):244-249.
7. Riley JL 3rd, Gilbert GH. Orofacial pain symptoms: an interaction between age and sex. *Pain.* 2001;90(3):245-256.
8. Pehling J, Schiffman E, Look J, Shaefer J, Lenton P, Friction J. Interexaminer reliability and clinical validity of the temporomandibular index: a new outcome measure for temporomandibular disorders. *J Orofac Pain.* 2002;16(4):296-304.
9. Huskisson EC. Measurement of pain. *Lancet.* 1974;2(7889):1127-1131.
10. Okeson JP, ed. Orofacial pain. *Guidelines for assessment, diagnosis, and management.* Chicago, IL: Quintessence Publishing Co, Inc; 1996:116-117.
11. Dworkin SF, Huggins KH, LeResche L, et al. Epidemiology of signs and symptoms in temporomandibular disorders: clinical signs in cases and controls. *J Am Dent Assoc.* 1990;120(3):273-281.
12. McNamara JA Jr, Seligman DA, Okeson JP. Occlusion, orthodontic treatment, and temporomandibular disorders: a review. *J Orofac Pain.* 1995;9(1):73-90.
13. Osborn JW. Internal derangement and the accessory ligaments around the temporomandibular joint. *J Oral Rehabil.* 1995;22(10):731-740.
14. Kalamir A, Pollard H, Vitiello AL, Bonello R. Manual therapy for temporomandibular disorders: a review of the literature. *J Bodyw Mov Ther.* 2007;11(1):84-90.

15. Milam SB. Pathogenesis of degenerative temporomandibular joint arthritides. *Odontology*. 2005;93(1):7-15.
16. Upledger JE. *Craniosacral Therapy II: Beyond the Dura*. Seattle, WA: Eastman Press; 1987.
17. Liem T, McPartland JM, Skinner E. *Cranial Osteopathy: Principles and Practice*. 2nd ed. New York, NY: Elsevier Churchill Livingstone; 2004:418-419.
18. Mori TA, Beilin LJ. Omega-3 fatty acids and inflammation. *Curr Atheroscler Rep*. 2004;6(6):461-467.
19. Frymann VM. Cranial osteopathy and its role in disorders of the temporomandibular joint. *Dent Clin North Am*. 1983;27(3):595-611.
20. Frank CB. Ligament structure, physiology and function. *J Musculoskel Neuron Interact*. 2004;4(2):199-201.
21. Osborn JW. A model to describe how ligaments may control symmetrical jaw opening movements in man. *J Oral Rehabil*. 1993;20(6):585-604.
22. Williams PL, Warwick R, Dyson M, Bannister LH, eds. *Gray's Anatomy*. 37th ed. Edinburgh, UK: Churchill Livingstone; 1989:743-772.
23. Burch JG. The cranial attachment of the sphenomandibular (tympanomandibular) ligament. *Anat Rec*. 1966;156(4):433-437.
24. Bumann A, Lotzmann U, Mah J. *TMJ Disorders and Orofacial Pain: The Role of Dentistry in a Multidisciplinary Diagnostic Approach*. New York, NY: Thieme Medical Publishers; 2002:30.
25. Garg A, Townsend G. Anatomical variation of the sphenomandibular ligament. *Aust Endod J*. 2001;27(1):22-24.
26. Testut L, Latarjet A. *Traité d'Anatomie Humaine*. Vol I. Paris, France: Doin & Cie; 1971:149.
27. Testut L, Latarjet A. *Traité d'Anatomie Humaine*. Vol V. Paris, France: Doin & Cie; 1971:842.
28. Piagkou M, Anagnostopoulou S, Kouladouros K, Piagkos G. Eagle's syndrome: a review of the literature. *Clin Anat*. 2009;22(5):545-558.
29. Bozkir MG, Boğa H, Dere F. The evaluation of elongated styloid process in panoramic radiographs in edentulous patients. *Turk J Med Sci*. 1999;29(4):481-485.
30. Keur JJ, Campbell JPS, Mc Carthy JF, Ralph WJ. The clinical significance of the elongated styloid process. *Oral Surg Oral Med Oral Pathol*. 1986;61:399-404.
31. Alomar X, Medrano J, Cabratosa J, et al. Anatomy of the temporomandibular joint. *Semin Ultrasound CT MR*. 2007;28(3):170-183.
32. Eagle WW. Elongated styloid process; symptoms and treatment. *AMA Arch Otolaryngol*. 1958;67(2):172-176.
33. Shimada K, Gasser RF. Morphology of the mandibulo-stylohyoid ligament in human adults. *Anat Rec*. 1988;222(2):207-210.
34. Shimada K, Gasser RF. Morphology of the pterygomandibular raphe in human fetuses and adults. *Anat Rec*. 1989;224(1):117-122.
35. Kandel ER, Schwartz JH, Jessell TM. *Principles of Neural Science*. 3rd ed. New York, NY: Elsevier Science Publication Co; 1991:721.
36. Lang J. *Clinical Anatomy of the Masticatory Apparatus and Peripharyngeal Spaces*. New York, NY: Thieme Medical Publishers; 1995:66.
37. Lintonbon D. The osteopathic approach to the temporomandibular joint (TMJ). *Positive Health Online*. 2006;(128). <http://www.positivehealth.com/article-view.php?articleid=1985>. Accessed January 19, 2011.
38. Magoun HI, ed. *Osteopathy in The Cranial Field*. 3rd ed. Meridian, ID: Sutherland Cranial Teaching Foundation; 1976:1-72.
39. Upledger JE, Vredevoogd JD. *Craniosacral Therapy*. Seattle, WA: Eastland Press; 1983:77-87.
40. Yin CS, Lee YJ, Lee YJ. Neurological influences of the temporomandibular joint. *J Bodyw Mov Ther*. 2007;11(4):285-294.
41. Sturdivant J, Friction JR. Physical therapy for temporomandibular disorders and orofacial pain. *Curr Opin Dent*. 1991;1(4):485-496.
42. Hruby RJ. The total body approach to the osteopathic management of temporomandibular joint dysfunction. *J Am Osteopath Assoc*. 1985;85(8):502-510.
43. Larsen NJ. Osteopathic manipulative contribution to treatment of TMJ syndrome. *Int J Osteopath Med*. 1976;3:15-27.
44. Monaco A, Cozzolino V, Cattaneo R, Cutilli T, Spadaro A. Osteopathic manipulative treatment (OMT) effects on mandibular kinetics: kinesiographic study. *Eur J Paediatr Dent*. 2008;9(1):37-42.
45. Cuccia AM, Caradonna C, Annunziata V, Caradonna D. Osteopathic manual therapy versus conventional conservative therapy in the treatment of temporomandibular disorders: a randomized controlled trial. *J Bodyw Mov Ther*. 2010;14(2):179-184.
46. Dyhre-Poulsen P, Krosgaard MR. Muscular reflexes elicited by electrical stimulation of the anterior cruciate ligament in humans. *J Appl Physiol*. 2000;89(6):2191-2195.
47. Solomonow M, Zhou B, Baratta RV, Lu Y, Harris M. Biomechanics of increased exposure to lumbar injury caused by cyclic loading: part 1. Loss of reflexive muscular stabilization. *Spine (Phila Pa 1976)*. 1999;24(23):2426-2434.
48. Manolopoulos L, Vlastarakos PV, Georgiou L, Giotakis I, Loizos A, Nikolopoulos TP. Myofascial pain syndromes in the maxillofacial area: a common but underdiagnosed cause of head and neck pain. *Int J Oral Maxillofac Surg*. 2008;37(11):975-984.
49. Yahia LH, Pigeon P, DesRossiers EA. Viscoelastic properties of the human lumbodorsal fascia. *J Biomed Eng*. 1993;15(5):425-429.
50. Schleip R, Klingler W, Lehmann-Horn F. Active fascial contractility: Fascia may be able to contract in a smooth muscle-like manner and thereby influence musculoskeletal dynamics. *Med Hypotheses*. 2005;65(2):273-277.

(continued on the next page)

Appendix

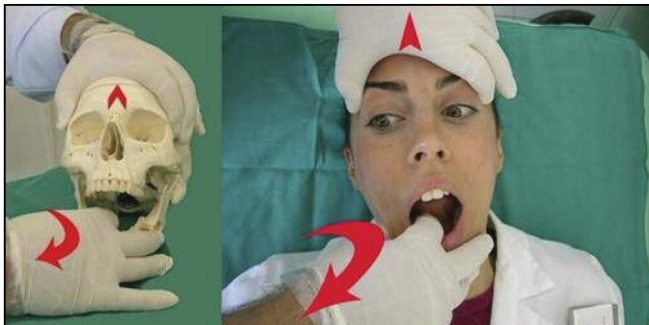We describe specific manipulative techniques for accessory ligaments of the temporomandibular joint, including the sphenomandibular, stylomandibular, and pterygomandibular ligaments. These techniques are designed to reduce ligament dysfunction and to retrain the involuntary neuromuscular, reflexive control of posture and balance.

For all of the described techniques, the patient is asked to take a comfortable supine position, and the therapist is positioned at the head of the patient. Each described technique may continue until the operator senses a release of the ligament treated.

Sphenomandibular Ligament

First Technique

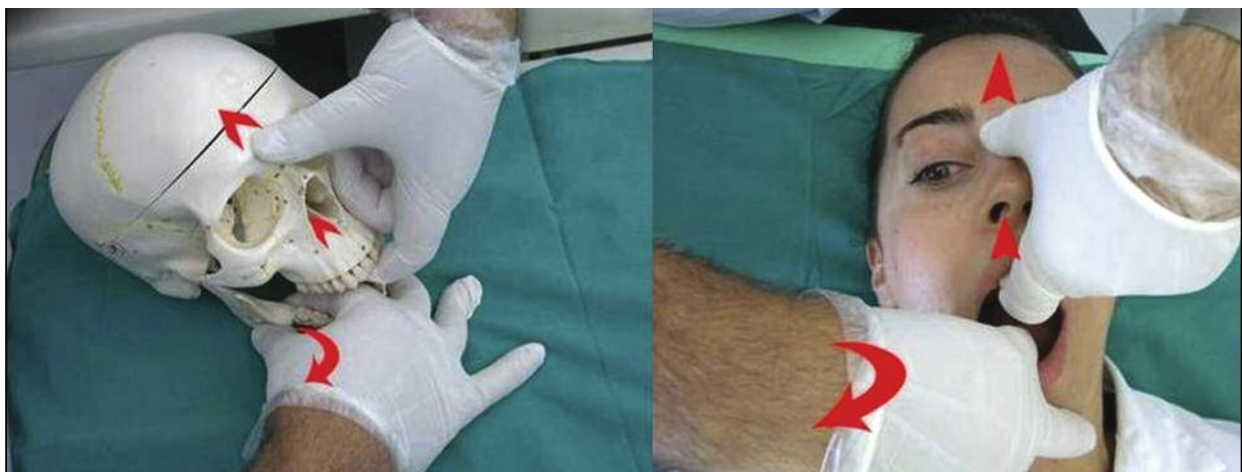With the forefinger and the thumb, grasp the alisphenoids to stabilize the sphenoid bone. With the other hand, put the forefinger on the lingula at the level of the mandibular foramen with an inclination of about 50°, according to the biomechanical line of balance of ligamentous tension. Gently pull inferiorly, laterally, and anteriorly, following the course of ligament (*Supplemental Figure 1*). If there is an abnormal increase in the tension of the sphenomandibular ligament, the alisphenoid on the tested side will move superiorly.



Supplemental Figure 1. Technique for the release of the sphenomandibular ligament.

Second Technique

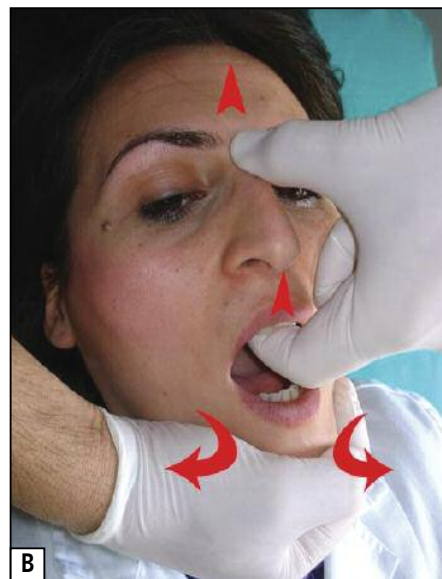
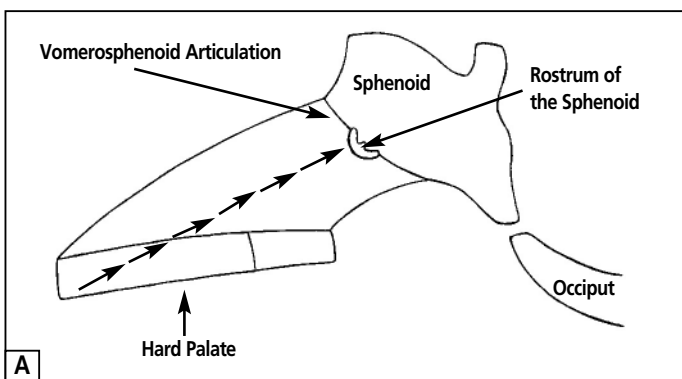
Put the middle finger on the hard palate (at vomer level) and the thumb on the metopic suture to stabilize the sphenoid bone. With other hand, put the forefinger, internally, at mandibular foramen level with an inclination of about 50°, according to the biomechanical line of balance of ligamentous tension. Gently pull the mandible inferiorly, laterally, and anteriorly, following the course of ligament (*Supplemental Figure 2*).



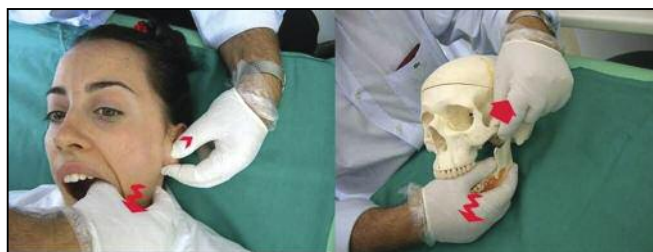Supplemental Figure 2. Technique for the release of the sphenomandibular ligament.

Third Technique (Bilateral)

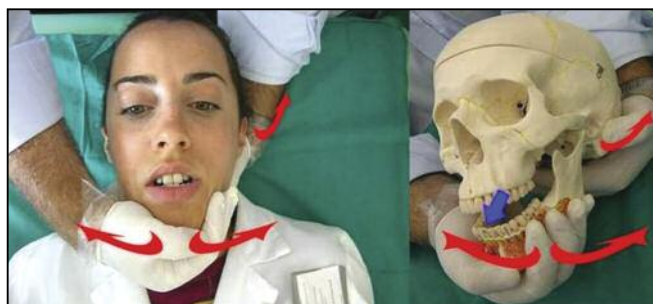Put the middle finger on the hard palate (at vomer level) and the thumb on the metopic suture to stabilize the sphenoid bone (Supplemental Figure 3A). With the other hand, carry out a gentle lateral oscillation of the mandible (Supplemental Figure 3B).



Supplemental Figure 3. (A) Image depicting pressure points for release of the sphenomandibular ligament. Pressure is applied to the hard palate, causing compression of the vomer into the rostrum of the sphenoid. Adapted from Upledger JE, Vredevoogd JD. *Craniosacral Therapy*. Seattle, WA: Eastland Press; 1983. (B) Image depicting technique for the release of the sphenomandibular ligament.



Supplemental Figure 4. Technique for the release of the stylo-mandibular ligament.



Supplemental Figure 5. Technique for the release of the stylo-mandibular ligament.

Stylomandibular Ligament First Technique

Grip the zygomatic process with the thumb and the forefinger. Position the middle finger in the external acoustic meatus and the ring finger on the mastoid process to stabilize the temporal bone and to prevent posterior rotation of the temporal bone. With the other hand, position outwardly the forefinger at mandibular angle (gonion), and gently move the mandible in an anterior and slightly lateral and inferior direction, with an inclination of about 30°, according to the biomechanical line of balance of ligamentous tension, following the course of ligament (Supplemental Figure 4).

Second Technique (Bilateral)

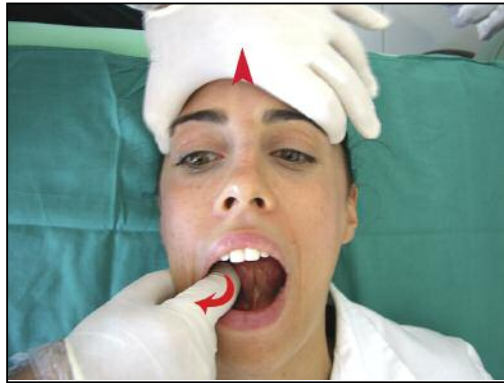Hold both mastoid processes in one hand. With the other hand, carry out a gentle lateral oscillation of the mandible during opening and closing jaw movements with forward mandibular positioning. This technique can be used to treat both stylomandibular ligaments (Supplemental Figure 5).

(continued)

Appendix (continued)

Pterygomandibular Ligament (Pterygomandibular Raphe)**First Technique**

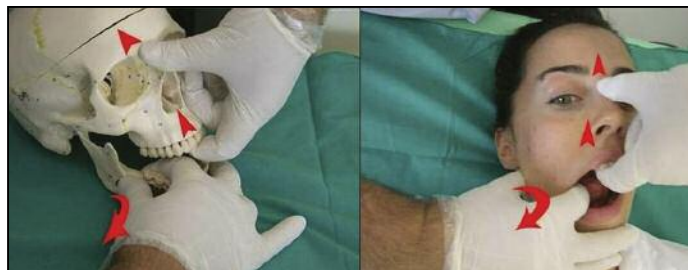Grasp the alisphenoid with the forefinger and the thumb to stabilize the sphenoid bone. Position the forefinger of the other hand obliquely in the oral cavity at second molar level. With the thumb, grip the angle of the mandible. Move gently the forefinger with an inclination of about 70°, in a lateral and anterior direction, according to the biomechanical line of balance of ligamentous tension, following the course of ligament (*Supplemental Figure 6*).



Supplemental Figure 6. Technique for the release of the pterygomandibular ligament.

Second Technique

Put the middle finger on the hard palate (at vomer level) and the thumb on the metopic suture to stabilize the sphenoid bone. Position the forefinger of the other hand obliquely in the oral cavity at second molar level. With the thumb, grip the angle of the mandible. Move gently the forefinger with an inclination of about 70°, in a lateral and anterior direction, according to biomechanical line of balance of ligamentous tension, following the course of ligament (*Supplemental Figure 7*).



Supplemental Figure 7. Technique for the release of the pterygomandibular ligament.