

See discussions, stats, and author profiles for this publication at: <https://www.researchgate.net/publication/244877577>

Manual therapy for temporomandibular disorders: A review of the literature

Article in *Journal of Bodywork and Movement Therapies* · January 2007

DOI: 10.1016/j.jbmt.2006.07.003

CITATIONS

43

READS

7,448

4 authors, including:



Allan Kalamir

Macquarie University

6 PUBLICATIONS 189 CITATIONS

[SEE PROFILE](#)



Henry Peter Pollard

Central Queensland University

167 PUBLICATIONS 2,494 CITATIONS

[SEE PROFILE](#)



Rod Bonello

Murdoch University

34 PUBLICATIONS 614 CITATIONS

[SEE PROFILE](#)

Some of the authors of this publication are also working on these related projects:

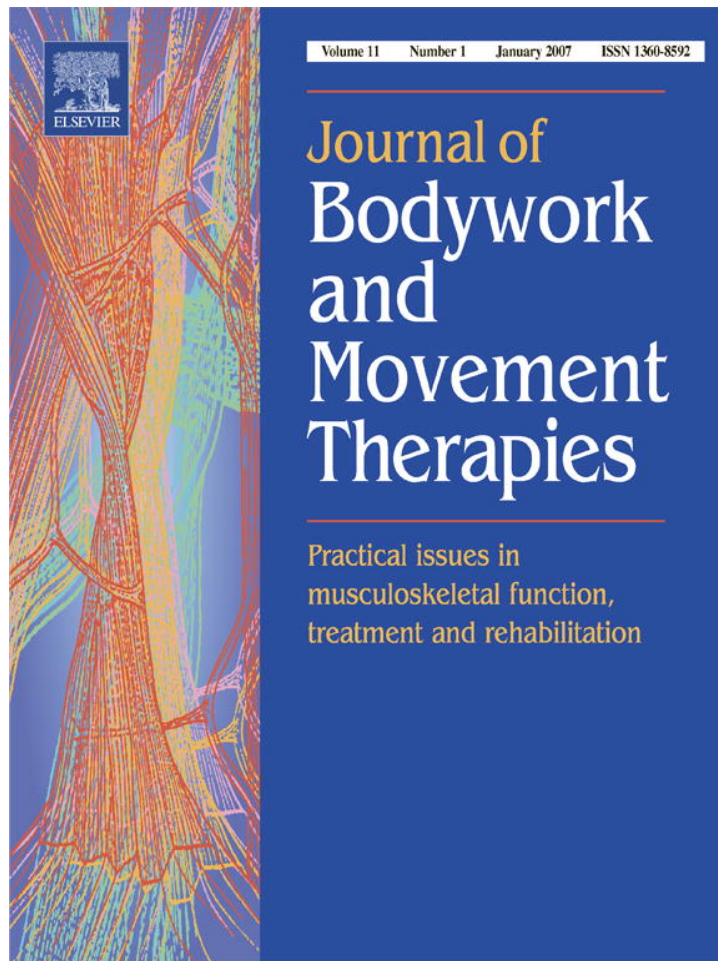


The studies we did on the 'Tunnel Vision' information; visual perception loss, migraine, interictal migraine, hypoperfusion, ischaemic penumbra, pet scanning, etc. [View project](#)



Masters Research Project [View project](#)

Provided for non-commercial research and educational use only.
Not for reproduction or distribution or commercial use.



This article was originally published in a journal published by Elsevier, and the attached copy is provided by Elsevier for the author's benefit and for the benefit of the author's institution, for non-commercial research and educational use including without limitation use in instruction at your institution, sending it to specific colleagues that you know, and providing a copy to your institution's administrator.

All other uses, reproduction and distribution, including without limitation commercial reprints, selling or licensing copies or access, or posting on open internet sites, your personal or institution's website or repository, are prohibited. For exceptions, permission may be sought for such use through Elsevier's permissions site at:

<http://www.elsevier.com/locate/permissionusematerial>



REVIEW

Manual therapy for temporomandibular disorders: A review of the literature

Allan Kalamir, BSc, MChiro, MSc(Hons)(Cand)*, Henry Pollard, BSc, GradDC, MSportSc, PhD, Andrew L. Vitiello, BSc, MChiro, PhD(Cand), Rod Bonello, BSc, DC, DO, MHA, FICC

Macquarie Injury Management Group, Department of Health and Chiropractic, Macquarie University, NSW 2109, Australia

Received 22 May 2006; received in revised form 18 July 2006; accepted 19 July 2006

KEYWORDS

Manipulation;
Temporomandibular;
Exercise;
Massage;
Manual therapy;
Chiropractic;
Osteopathy

Summary The contemporary biopsychosocial health paradigm emphasizes a reversible and conservative approach to chronic pain management. Manual therapy for temporomandibular disorders (TMDs) claims to fulfil these criteria. An assessment of the utilization and efficacy of manual therapy for this condition is therefore required. A review of the literature pertaining to manual therapy for TMDs was undertaken between September and December 2005. Keywords used in the search were: TMD, manual therapy, massage, manipulation, mobilization, adjustment, chiropractic, osteopathy, physiotherapy, exercise. The four member reviewer panel identified eight ($n = 8$) randomized controlled trials of sufficiently reliable power to be suitable for inclusion in the review, of which only three included manipulative treatment of the temporomandibular joint. The results of manual therapy trials for this condition suggest that manual therapy is a viable and useful approach in the management of TMD. Manual therapy has also been shown to be more cost effective and less prone to side effects than dental treatment. Some manipulative techniques for the TMJ are described.

© 2006 Elsevier Ltd. All rights reserved.

Introduction

Temporomandibular disorder (TMD) is described as “a collective term embracing a number of clinical

problems that involve the masticatory musculature, the temporomandibular joint (TMJ) and associated structures, or both” (Okeson, 1996). It has been described more simply as a “group of musculoskeletal conditions of the temporomandibular region” (Laskin et al., 1982). That the disorder is now generally accepted to be a complex biopsychosocial phenomenon belies the fact that

*Corresponding author. C/-: 249 Edensor Road, Edensor Park, NSW 2176, Australia.

E-mail address: thechiro@tpg.com.au (A. Kalamir).

its active management is still dominated by the dental field, utilizing primarily mechanistic stomatognathic models.

A typical statistical review suggests that 50% of TMJ disorders are self-limiting, 25% are managed with NSAIDs and muscle relaxants, 20% are treated with oral appliances and 1–2% end up in surgery (Westesson, 2004). This would presumably leave about 3% of sufferers to undergo the other available treatment modalities described in the literature such as physiotherapy, chiropractic, massage, cognitive behavioural therapy (CBT), biofeedback, stress counselling, acupuncture and other therapies. Combinations of treatments were not reported. In a survey of complementary and alternative medicine (CAM) use for TMD 22.6% of sufferers had used CAM therapies for temporomandibular pain. Of these, 12.5% of sufferers utilized “relaxation therapy” and 9% utilized chiropractic care (Raphael et al., 2003). Raphael reported further that over 50% of sufferers did not report their symptoms, and that there was a high incidence of self-medicating. These findings are reflected elsewhere (Sternbach, 1986). CAM use among TMD sufferers has similarly been reported to be about 62.5%, with the most utilized care being the “hands on” therapies of massage, acupuncture and chiropractic. Massage was rated by surveyed sufferers as both the most frequently utilized and the most helpful (DeBar et al., 2003). It appears that the use of, and satisfaction with non-occlusal therapies for the management of TMD may therefore be underestimated and underappreciated. This situation requires a better understanding of the pathogenesis of TMD as well as increased construction of quality randomized controlled trials (RCTs) of the efficacy of different treatment approaches both in comparison and multimodally. It is the purpose of this paper to review RCT evidence for manual therapy in light of the changing paradigm for chronic pain management.

Dental approaches

The mechanistic occlusal model of Costen and later followers insisted on the centric placement of the mandibular condyle within the glenoid fossa of the temporal bone for optimal jaw joint function. Anterior disc displacement, compression of retro-discal neurovascular structures, reactive craniofacial myospasm, capsulitis, fibrosis and aberrant temporomandibular motion were commonly thought to be secondary to malocclusion. Eventual pathological changes to these structures were then

believed to be responsible for joint sounds and pain (Mohl, 1988).

While malocclusion is widely accepted as being causative of jaw dysfunction, there is some contradictory evidence in the literature associating it with craniofacial symptoms (Alamoudi, 2000; Ali et al., 2003; Ciancaglini et al., 2002; Gesch et al., 2004; Henrikson et al., 1997; Kahn et al., 1999; Liu et al., 2000; Manfredini et al., 2004a; Tuerlings and Limme, 2004; Yatani et al., 1998). Manfredini's study concluded that psychoemotional variables were more identifiable in TMD than occlusal ones. Some of the earliest descriptions of TMD (and other synonyms) recognized psychoemotional distress as an important aetiological co-factor (Wakeley, 1929). Head posture has been identified as being a more significant co-factor than occlusion (Ciancaglini et al., 2003).

Bruxism—a widely used, yet poorly defined phenomenon is often viewed as a pathological stress-coping parafunction, and has also long been thought to be another primary factor in the onset of TMD. Its definition, phylogenesis, onset and natural history are still subject to wide debate, with the purported relationship between bruxism and TMD remaining a controversial subject (De Meyer and De Boever, 1997; Manfredini et al., 2004b; Pergamalian et al., 2003). Nevertheless, it would appear that many treatments continue to be largely centred on limiting bruxism and improving the occlusion instead of addressing psychoemotional distress or soft tissue reaction and degenerative change. In recent years however, there has been a growing call for multidisciplinary intervention from many academics of various disciplines who recognize the shortcomings of a purely mechanistic approach to TMD management (Dworkin and LeResche, 1992; Epker and Gatchel, 2000; McNeill, 1990, 2000).

Manual approaches

Manual therapy (including soft tissue techniques, mobilization, exercise and manipulation) is postulated to reduce local ischaemia, stimulate proprioception, break fibrous adhesions, stimulate synovial fluid production and reduce pain among other effects (Simons et al., 1998). Manual soft tissue therapy has been used as an adjunct to occlusal treatment and as an ancillary procedure post-surgically for some decades. It is therefore widely accepted as a legitimate, though limited and somewhat secondary treatment modality in contemporary TMD management. The osteopathic and

chiropractic health fields have a long history of intraoral and cranial manual techniques aimed at addressing orofacial dysfunction, but RCTs of their efficacy are lacking. The reduction of condyle dislocations and disc displacements has been well described, but only recently has manipulative therapy been considered by the wider medical field as a stand alone treatment, or alternative to otherwise irreversible intra articular lavage and surgical techniques. A general exception to this is emergency reduction of acute dislocation, usually performed by medical practitioners utilizing sedation or anaesthetic.

Early manual approaches to jaw pain advocated a primarily myogenous psychogenic model of TMD, for which the use of manual therapy in the management of this disorder may afford a primary, conservative, non-invasive and reversible approach to care (Schwartz, 1955). Unlike splint therapy and orthodontic work whose myofascial effects are secondary to those of structural change, manual therapy aims to directly rehabilitate local myofascial and disco-ligamentous dysfunction. Manual therapy however, like dental treatment does not generally claim to treat the psychoemotional disorders that have commonly been associated with TMD.

TMD sufferers have been found to complain of pain or sensitivity within the masticatory muscles, with the regions of the lateral pterygoid, masseter and temporalis muscles being of particular significance (Tsukert and Rafaeli, 1978). Other commonly reported muscle groups include the digastric, sternocleidomastoid, posterior cervical muscles and the scalenes (Whyte Ferguson and Gerwin, 2004). Myofascial trigger points (MTP) within muscle tissue are postulated to arise from repetitive strains or postural fatigue (Simons et al., 1998). Damage to the temporomandibular soft tissue structures may result from mechanical activities such as excessive chewing of gum, consuming nuts and other such crunchy objects, prolonged conversation, reactive muscle spasms due to dental work, direct trauma, yawning and even thumb or pacifier sucking during childhood (Simons et al., 1998).

Soft tissue treatments and exercise

Published clinical trials involving jaw exercises, mobilizations and massage rarely describe the techniques they use in any detail. This poses obvious problems for any researcher attempting to reproduce or assess the methodology of a study. Conversely, technique manuals and case studies

commonly describe both static ischaemic pressure releases, friction and myofascial spray and stretch techniques (Cohen and Pertes, 2002; Greenfield, 2005; Whyte Ferguson and Gerwin, 2004). Active and passive range of motion exercises aimed at restoring physiological movements include opening, laterotrusion (lateral deviation), protrusion and retrusion. Resistance exercises in the form of isometrics and muscle energy techniques are also commonly described.

Several studies have been shown to have significant success in the treatment of TMD through combined muscle treatments such as massage, electro-physical therapies (EPT), mobilization, bio-feedback and jaw exercise (Cridler and Glaros, 1999; Gray et al., 1995; Michelotti et al., 2000; van der Glas et al., 2000). One study found that when comparing manual therapy alongside splint therapy 46% of participants demonstrated complete improvement on both a VAS scale and range of motion assessment, while 40% demonstrated partial improvement, and no patients worse as a result of the manual therapy (Heloe and Hinberg, 1980). The splint group showed similar results but it was concluded that overall the manual approach was more cost effective. Exercise therapy for MRI identified disc displacement TMD participants has shown significant reduction in symptoms and clicking compared to control during both post treatment and at 6-month follow-up assessment periods, indicating that even so-called non-myogenous (i.e. arthrogenous or degenerative joint) cases of TMD may be effectively managed without occlusal work (Yoda et al., 2003). These results are supported elsewhere, utilizing a combination of non-steroidal antiinflammatory drugs, physical therapy and exercises (Yuasa and Kurita, 2001). Treating arthrogenous TMD patients with passive and active exercises, manual therapy, postural correction and relaxation techniques has resulted in statistically significant improvements in pain, impairment and range of motion within the treatment group (Nicolakis et al., 2001). Long-term follow-up studies demonstrated continued success (Nicolakis et al., 2002). Another study showed significant subjective and objective improvement in symptoms and function in 81% of patients treated with physical therapy (Suvinen et al., 1997), though this study lacked a control group. Mobilization techniques have been found to be useful in the short term via self-reported outcome measures (Taylor et al., 1994), though this study involved only a small convenience sample of TMD sufferers. Similarly, good objective outcome measures have been found in effectiveness, responsiveness and satisfaction in a small study of TMD patients

receiving two 1 h TMD specific massages (Dixon et al., 2004).

The treatment of MTPs within masticatory muscles by injection has been described at length (Cohen and Pertes, 2002) but has little support in the literature. There have been some documented cases of the use of Botulin toxin (BoTox) to combat hypertonicity of muscles and while successful in relieving cases of myopathy (Moore and Wood, 1997), it poses a significant risk of excessive joint laxity and dislocation (Tan et al., 2001).

Manipulative treatment for TMD

These interventions generally include either manipulative procedures involving the TMJ, or alternatively the spine and lower extremities (to improve posture and proprioception). Various descriptions and techniques are given in the chiropractic, osteopathic, physiotherapy, orthopaedic and emergency medicine literature.

Manipulation of the jaw

Temporomandibular manipulation is based on the premise that the curvilinear motion of the condyle can be interrupted should the articular disc be held anteriorly along the articular eminence through adhesions, myospasm or disc deformity. Since the TMJ is also capable of lateral glide, deviations and deflections also need to be addressed. Conditions are usually described as either acute or chronic and in terms of their functional capacity (open or closed lock, restricted range of motion) and tissue involvement (myogenous, arthrogenous, combined). Three approaches are generally described in the literature:

1. *Manipulation of the condyle onto the anteriorly displaced disc:* These manipulative techniques are postulated to be particularly useful in the case of acute closed or open lock and are meant to reduce the condyle back onto an anteriorly displaced disc. The use of this type of manipulation for the reduction of a closed lock has been used with mixed results, and has been performed both under anaesthetic (Foster et al., 2000), and without (Jagger, 1991; Kurita et al., 1999). The rest of the literature predominantly describes case studies (Curl, 1991; Saghafi and Curl, 1995; Segami et al., 1990). Techniques usually involve unilaterally or bilaterally contacting the lower molars with the thumbs

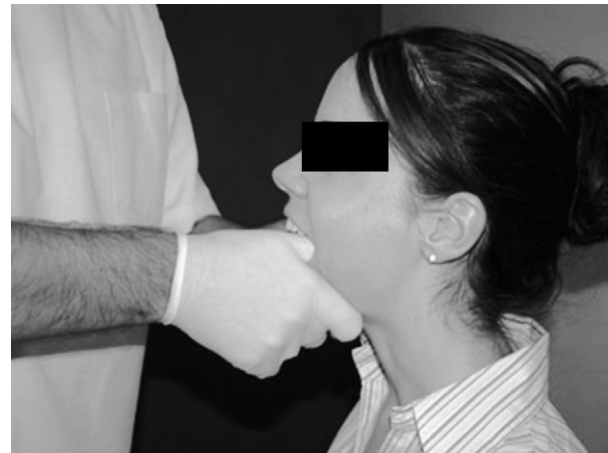

Figure 1 Manipulation of the condyle.

intraorally and thrusting or distracting the mandible anteroinferiorly (see Fig 1).

2. *Manipulating the anteriorly displaced articular disc posteriorly:* This technique is used in conditions where there is anterior disc displacement but in which the condyle regains congruency. The disc is engaged onto the condyle through partial opening of the mouth. A poster-osuperior manipulation of the TMJ along the articular eminence has been postulated to break adhesions, improve disc translation and stretch masticatory muscles (Esposito and Rigney, 2004), but poses a greater risk of compressive injury to the retrodiscal tissues and haemarthrosis (Bergmann et al., 1993). No published studies have been found validating this type of technique.
3. *Manipulating the condyle in a lateromedial direction:* These techniques address mediolateral joint restrictions, which commonly arise due to structural asymmetry or capsular and ligamentous injuries sustained by a blow to the side of the jaw. It may also stretch fibres of the contralateral lateral pterygoid along with the homolateral posterior temporalis (which antagonizes it) when in a state of spasm. Mostly these techniques are described as assisted or resisted mobilizations and exercises but may also be performed as thrust manoeuvres. No published studies have been found validating this type of technique (Figs. 2–4).

Spinal manipulation and postural correction

There are no Medline indexed RCTs of spinal manipulation for TMD, although there have been a few case studies (Alcantara et al., 2002;

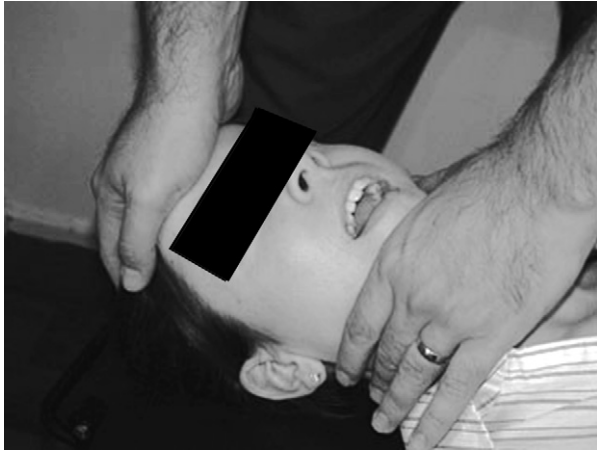

Figure 2 Supine manipulation of the anteriorly displaced disc.

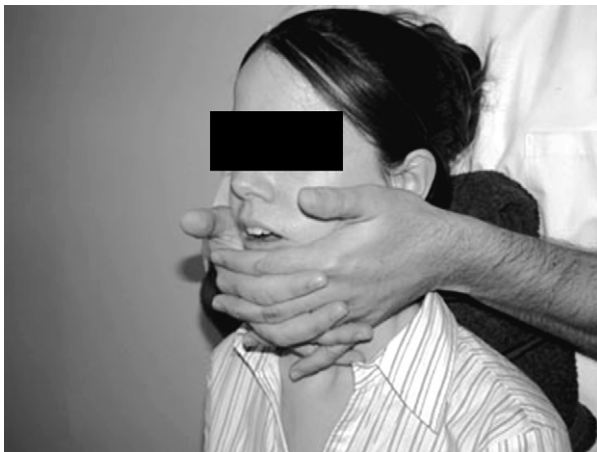

Figure 3 Sitting manipulation of the anteriorly displaced disc.

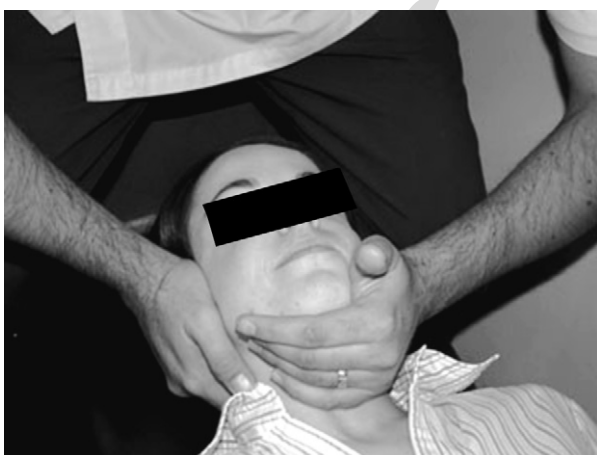

Figure 4 Lateromedial manipulation of the condyle.

Devocht et al., 2003; Gregory, 1993; Hruby, 1985), all of which had positive subjective and objective outcomes. A full spine and TMJ protocol was used in

a small prospective study utilizing a chiropractic adjusting instrument (Devocht et al., 2003), with positive objective outcomes. The authors believe that in light of the neurological relationships that exist between the TMJ and posture, robust studies of spinal manipulative therapy, dural tension techniques and cranial sutural techniques for TMD would be of potential scientific interest. Studies of the effect on TMD of plantar arch stabilization through the use of orthotics may also prove useful to clinicians.

Conclusion

The few quality RCTs on manual therapy for TMD indicate that it is a viable, cost effective and reversible mode of conservative treatment. The results of multidisciplinary, multimodal treatment involving the dentition, spine and extremities strongly suggests that the use of manual therapy for TMD is expected to increase in the future. Chiropractic and osteopathic manipulative techniques of the TMJ, while remaining relatively untested within the literature, may have much to contribute to future TMD research. The authors believe that well constructed multidisciplinary studies would prove useful in the betterment of our understanding and treatment of this complex multifactorial disorder.

Acknowledgements

Written consent was obtained from the demonstration model for publication of photographs in the review. The authors declare that they have no competing interests.

References

- Alamoudi, N., 2000. The correlation between occlusal characteristics and temporomandibular dysfunction in Saudi Arabian children. *Journal of Clinical Pediatric Dentistry* 24 (3), 229–236.
- Alcantara, J., Plaugher, G., Klemp, D.D., et al., 2002. Chiropractic care of a patient with temporomandibular disorder and atlas subluxation. *Journal of Manipulative and Physiological Therapeutics* 25 (1), 63–70.
- Ali, I.M., Yamada, K., Alkhamrah, B., et al., 2003. Relationship between occlusal curvatures and mandibular deviation in orthodontic patients with temporomandibular disorders. *Journal of Oral Rehabilitation* 30 (11), 1095–1103.
- Bergmann, T., Peterson, D.R., Lawrence, D.J., 1993. Chiropractic technique. *Extraspinal Techniques*. Churchill Livingstone, New York, 342–54pp (Chapter 6).

- Ciancaglini, R., Gherlone, E.F., Redaelli, S., et al., 2002. The distribution of occlusal contacts in the intercuspal position and temporomandibular disorder. *Journal of Oral Rehabilitation* 29 (11), 1082–1090.
- Ciancaglini, R., Colombo-Bolla, G., Gherlone, E.F., et al., 2003. Orientation of craniofacial planes and temporomandibular disorder in young adults with normal occlusion. *Journal of Oral Rehabilitation* 30 (9), 878–886.
- Cohen, H.V., Pertes, R.A., 2002. Myofascial pain and fibromyalgia. Trigger point management. *Diagnosis and Management of Orofacial Pain*. Mosby, New York, pp. 175–200.
- Crider, A.B., Glaros, A.G., 1999. A meta-analysis of EMG biofeedback treatment of temporomandibular disorders. *Journal of Orofacial Pain* 13 (1), 29–37.
- Curl, D.D., 1991. *The Chiropractic Approach to Temporomandibular Disorders*. Williams & Wilkins, Baltimore, 120pp.
- De Meyer, M.D., De Boever, J.A., 1997. The role of bruxism in the appearance of temporomandibular joint disorders. *Revue Belge de Medecine Dentaire* 52 (4), 124–138.
- DeBar, L.L., Vuckovic, N., Schneider, J., et al., 2003. Use of complementary and alternative medicine for temporomandibular disorders. *Journal of Orofacial Pain* 17 (3), 224–236.
- Devocht, J.W., Long, C.R., Zeidler, D.L., et al., 2003. Chiropractic treatment of temporomandibular disorders using the activator adjusting instrument: a prospective case series. *Journal of Manipulative and Physiological Therapeutics* 26 (7), 421–425.
- Dixon, M.W., Williams, L.A., Aickin, M., 2004. Developing a massage protocol for temporomandibular joint disorders. *Massage Therapy Journal* 43 (2), 108–115.
- Dworkin, S.F., LeResche, L., 1992. Research diagnostic criteria for temporomandibular disorders: review, criteria, examinations and specifications, critique. *Journal of Craniomandibular Disorders* 6 (4), 301–355.
- Epker, J., Gatchel, R.J., 2000. Prediction of treatment-seeking behavior in acute TMD patients: practical application in clinical settings. *Journal of Orofacial Pain* 14 (4), 303–309.
- Esposito, S., Rigney, C., 2004. *Manual of Peripheral Technique*. Department Health and Chiropractic Macquarie University.
- Foster, M.E., Gray, R.J., Davies, S.J., et al., 2000. Therapeutic manipulation of the temporomandibular joint. *British Journal of Oral and Maxillofacial Surgery* 38 (6), 641–644.
- Gesch, D., Bernhardt, O., Alte, D., et al., 2004. Malocclusions and clinical signs or subjective symptoms of temporomandibular disorders (TMD) in adults. Results of the population-based Study of Health in Pomerania (SHIP). *Journal of Orofacial Orthopedics* 65 (2), 88–103.
- Gray, R.J.M., Quayle, A.A., Hall, C.A., et al., 1995. *Physiotherapy* 81 (1), 47–51.
- Greenfield, A.D., 2005. The lateral pterygoid release to restore normal jaw motion: a case report. *Clinical Chiropractic* 8 (1), 27–32.
- Gregory, T.M., 1993. Temporomandibular disorder associated with sacroiliac sprain. *Journal of Manipulative and Physiological Therapeutics* 16 (4), 256–265.
- Heloe, B., Hinberg, A.N., 1980. A multiple treatment study of TMJ syndrome. *Acta Odontologica Scandinavica* 38 (2), 129–134.
- Henrikson, T., Ekberg, E.C., Nilner, M., 1997. Symptoms and signs of temporomandibular disorders in girls with normal occlusion and class II malocclusion. *Acta Odontologica Scandinavica* 55 (4), 229–235.
- Hruby, R.J., 1985. The total body approach to the osteopathic management of temporomandibular joint dysfunction. *Journal of the American Osteopathic Association* 85 (8), 502–510.
- Jagger, R.G., 1991. Mandibular manipulation of anterior disc displacement without reduction. *Journal of Oral Rehabilitation* 18 (6), 497–500.
- Kahn, J., Tallents, R.H., Katzberg, R.W., et al., 1999. Prevalence of dental occlusal variables and intraarticular temporomandibular disorders: molar relationship, lateral guidance, and nonworking side contacts. *Journal of Prosthetic Dentistry* 82 (4), 410–415.
- Kurita, H., Kurashina, K., Ohtsuka, A., 1999. Efficacy of a mandibular manipulation technique in reducing the permanently displaced temporomandibular joint disc. *Journal of Oral and Maxillofacial Surgery* 57 (7), 784–787 discussion 8.
- Laskin, D., Greenfield, W., Gale, E., et al., 1982. The president's conference on the examination, diagnosis and management of temporomandibular disorders. In: Laskin, D.G.W., Gale, E., Rugh, J., Neff, P., Alling, C., et al. (Eds.), *The President's Conference on the Examination, Diagnosis and Management of Temporomandibular Disorders*. American Dental Association, Chicago, 1983.
- Liu, Z.J., Yamagata, K., Kuroe, K., et al., 2000. Morphological and positional assessments of TMJ components and lateral pterygoid muscle in relation to symptoms and occlusion of patients with temporomandibular disorders. *Journal of Oral Rehabilitation* 27 (10), 860–874.
- Manfredini, D., Landi, N., Romagnoli, M., et al., 2004a. Psychic and occlusal factors in bruxers. *Australian Dental Journal* 49 (2), 84–89.
- Manfredini, D., Landi, N., Tognini, F., et al., 2004b. Occlusal features are not a reliable predictor of bruxism. *Minerva Stomatologica* 53 (5), 231–239.
- McNeill, C., 1990. *Craniomandibular Disorders—Guideline for Evaluation, Diagnosis, and Management*. Quintessence, Chicago, IL, 54pp.
- McNeill, C., 2000. Occlusion: what it is and what it is not. *Journal of California Dental Association* 28 (10), 748–758.
- Michelotti, A., Parisini, F., Farella, M., et al., 2000. Muscular physiotherapy in patients with temporomandibular disorders. Controlled clinical trial. *Minerva Stomatologica* 49 (11–12), 541–548.
- Mohl, N., 1988. *A Textbook of Occlusion*. Chicago, IL, Quintessence Books.
- Moore, A.P., Wood, G.D., 1997. Medical treatment of recurrent temporomandibular joint dislocation using botulinum toxin A. *British Dental Journal* 183 (11–12), 415–417.
- Nicolakis, P., Burak, E.C., Kollmitzer, J., et al., 2001. An investigation of the effectiveness of exercise and manual therapy in treating symptoms of TMJ osteoarthritis. *Journal of Craniomandibular Practice* 19 (1), 26–32.
- Nicolakis, P., Erdogmus, C.B., Kollmitzer, J., et al., 2002. Long-term outcome after treatment of temporomandibular joint osteoarthritis with exercise and manual therapy. *Journal of Craniomandibular Practice* 20 (1), 23–27.
- Okeson, J.P., 1996. *Orofacial Pain. Guidelines for assessment, diagnosis and management*. Quintessence Publishing Co., Chicago, 113–184pp.
- Pergamalian, A., Rudy, T.E., Zaki, H.S., et al., 2003. The association between wear facets, bruxism, and severity of facial pain in patients with temporomandibular disorders. *Journal of Prosthetic Dentistry* 90 (2), 194–200.
- Raphael, K.G., Klausner, J.J., Nayak, S., et al., 2003. Complementary and alternative therapy use by patients with myofascial temporomandibular disorders. *Journal of Orofacial Pain* 17 (1), 36–41.
- Saghafi, D., Curl, D.D., 1995. Chiropractic manipulation of anteriorly displaced temporomandibular disc with adhesion.

- Journal of Manipulative and Physiological Therapeutics 18 (2), 98–104.
- Schwartz, L.L., 1955. Pain associated with the temporomandibular joint. *Journal of the American Dental Association* 51, 934–937.
- Segami, N., Murakami, J., Iizuka, T., 1990. Arthrographic evaluation of disc position following mandibular manipulation technique for internal derangement with closed lock of the temporomandibular joint. *Journal of Craniomandibular Disorders* 4 (2), 99–108.
- Simons, D.G., Travell, J.G., Simons, L.S., et al., 1998. *Travell and Simons' Myofascial Pain and Dysfunction: the Trigger Point Manual*, vol. 1. Lippincott Williams and Wilkins, Baltimore, 5–44, 103–164pp.
- Sternbach, R.A., 1986. Pain and “hassles” in the United States: findings of the Nuprin pain report. *Pain* 27, 69–80.
- Suvinen, T.I., Hanes, K.R., Reade, P.C., 1997. Outcome of therapy in the conservative management of temporomandibular pain dysfunction disorder. *Journal of Oral Rehabilitation* 24 (10), 718–724.
- Tan, E.K., Lo, Y.L., Seah, A., et al., 2001. Recurrent jaw dislocation after botulinum toxin treatment for sialorrhoea in amyotrophic lateral sclerosis. *Journal of the Neurological Sciences* 190 (1–2), 95–97.
- Taylor, M., Suvinen, T., Reade, P., 1994. The effect of grade IV distraction mobilisation on patients with temporomandibular pain-dysfunction disorder. *Physiotherapy Theory and Practice* 10 (3), 129–136.
- Tsukert, A., Rafaeli, B., 1978. Muscle Pain Index in relation to pain dysfunction and dizziness associated with the myofascial pain dysfunction syndrome. *New York State Dental Journal* 46, 742–747.
- Tuerlings, V., Limme, M., 2004. The prevalence of temporomandibular joint dysfunction in the mixed dentition. *European Journal of Orthodontics* 26 (3), 311–320.
- van der Glas, H.W., Buchner, R., van Grootel, R.J., 2000. Comparison of treatment options for myogenous temporomandibular dysfunction. *Nederlands Tijdschrift voor Tandheelkunde* 107 (12), 505–512.
- Wakeley, C.P.G., 1929. The causation and treatment of displaced mandibular cartilage. *Lancet* ii, 543–545.
- Westesson P. Post Operative TMJ. <<http://urmc.rochester.edu/smd/rad/tmj/postopTMJ.htm>>. 2004.
- Whyte Ferguson, L., Gerwin, R., 2004. *Clinical Mastery in the Treatment of Myofascial Pain. Masticatory Myofascial Pain*. Lippincott Williams & Wilkins, Philadelphia, 32–54pp.
- Yatani, H., Minakuchi, H., Matsuka, Y., et al., 1998. The long-term effect of occlusal therapy on self-administered treatment outcomes of TMD. *Journal of Orofacial Pain* 12 (1), 75–88.
- Yoda, T., Sakamoto, I., Imai, H., et al., 2003. A randomized controlled trial of therapeutic exercise for clicking due to disk anterior displacement with reduction in the temporomandibular joint. *Journal of Craniomandibular Practice* 21 (1), 10–16.
- Yuasa, H., Kurita, K., 2001. Randomized clinical trial of primary treatment for temporomandibular joint disk displacement without reduction and without osseous changes: a combination of NSAIDs and mouth-opening exercise versus no treatment. *Oral Surgery Oral Medicine Oral Pathology Oral Radiology and Endodontics* 91 (6), 671–675.

Available online at www.sciencedirect.com

 ScienceDirect

Author's